

RECENT ADVANCES IN MANAGEMENT OF RECURRENT AND CHRONIC SINUSITIS: DIAGNOSIS

John R. Cherry, Consultant ENT Surgeon
Lancaster and Kendal hospitals

The management of acute sinusitis is primarily medical, and much of it is carried out successfully in general practice. Only those cases which fail to resolve, or are complicated, require surgical intervention. The management of recurrent and chronic sinusitis lies with the otolaryngologist, and much of it is surgical. In recent years, new techniques of diagnosis and treatment have emerged, and promise to improve the results of therapy, which have hitherto been disappointing in a significant proportion of well established cases.

The new approach emphasises the functional importance of the middle meatus of the nose in the causation of obstructed drainage from the larger sinuses, and hence of chronic sinus disease, whose pathogenesis is believed to arise largely from failure of normal mucociliary clearance. This is entirely logical. Most acute sinusitis arises in the course of viral upper respiratory infections, which temporarily destroy regional mucociliary function, allowing stasis of secretions which are already excessive in volume due to inflammation of the mucosa. The anatomy of the middle meatus (Fig. 1), although complex, shows clearly how critical the area is for drainage of the antrum, the anterior and middle ethmoid cells, and the frontal sinus (the superior meatus is similarly important for the posterior ethmoids, and the sphenoethmoidal recess for the sphenoids). These drainage areas, together with their bony anatomy and the middle and superior turbinate, are currently referred to as the osteomeatal complex, and are seen as the key to recurring and chronic infection of the major sinuses.

Coronal Section Of Nose And Sinuses

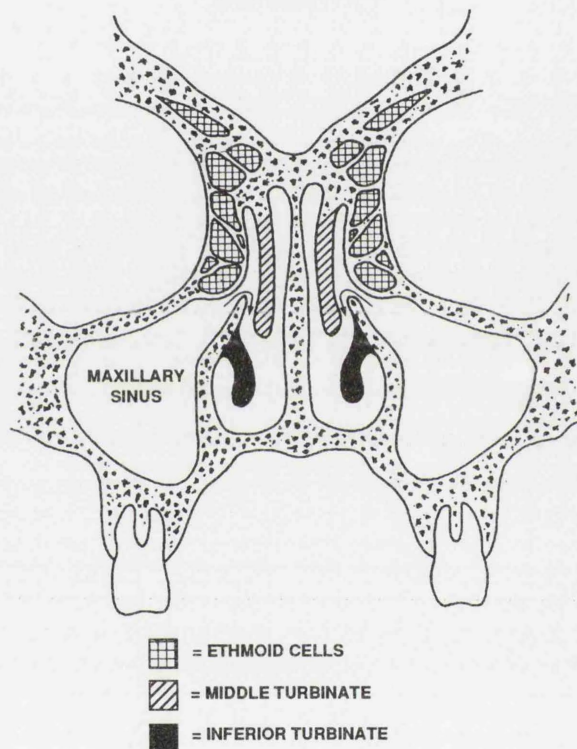


Fig 1b

meatus, with obstruction. More frequently, chronic mucosal disease within the ethmoid cells may produce obstruction. Thus chronic rhinitis, with or without polyps, may lead on to secondary sinusitis. Allergy remains a potent cause of rhinitis, while a significant proportion of those with chronic sinusitis have borderline immunologic deficiency. True defects of mucociliary function are less frequent, but they account for the combination of upper and lower airway infection which may be seen with or without the other features of Kartagener's syndrome.

How may this improved understanding be applied to diagnosis with the aid of modern technology? First, we must understand that the diagnosis of chronic sinusitis is often made wrongly. Both patients and their doctors may confuse rhinitis with infective sinusitis, while various types of recurring headache and facial pain are very common – far more so than painful chronic sinus disease, which is exceptional; most with chronic sinusitis present with purulent discharge, not pain. The history remains of vital importance, and I continue to stress the diagnostic value of diurnal variation in true sinus pain. As anyone with a head cold can tell us, secretion of mucus in the nose and sinuses varies

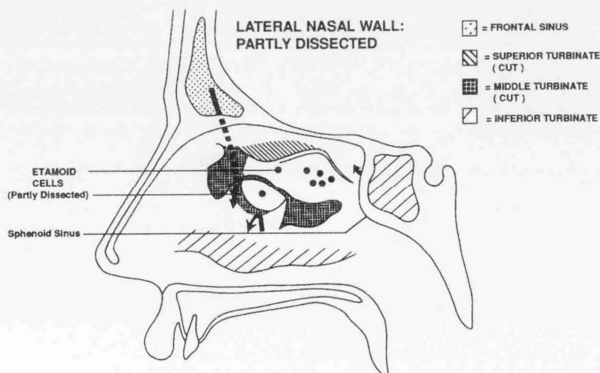


Fig 1a

These infections may develop for several reasons. There may be anatomical abnormalities, such as an extensively pneumatized middle turbinate, which may block the antral ostium. Anatomical variants in the ethmoid cells may do the same, as may a reversed (paradoxical) curvature of the middle concha. The traditional role of a deviated nasal septum is explained by resultant narrowing of the middle

through the day. It is minimal first thing in the morning, maximal in the middle of the day, and reduced again in the evening. The same is invariably true of sinus pain, and for the same reason: sinus pain equals mucus or pus under tension. Moreover, painful chronic sinusitis is invariably accompanied by purulent nasal or postnasal discharge, the latter in sufficient quantities to be hawked up and visualised by most patients, who can therefore report on its colour.

The rhinologist has always looked for pus in the nose and postnasal space when examining his patient, but traditional methods are very limited. The Thudichum speculum only allows the front one-third of the nasal fossa to be seen, and not even that much where the septum is substantially deviated. The postnasal mirror examination is only successful in around half of one's patients. Accumulation of enough mucopus to be visible by these methods is intermittent at best.

The modern rhinologist needs a better technique, which has been provided by fiberoptics and the Hopkins rod. With the fiberoptic laryngoscope, or, better, a rigid nasendoscope, the middle and superior meatuses may be inspected under surface anaesthesia in most cases. The former instrument also gives a clear view of the nasopharynx in all but the most violent of gaggers. With either of these, the surgeon may see the small stream of infected mucus which flows from the sinus ostia in almost every case of chronic disease, often passing back over the inferior turbinate into the postnasal space. Moreover, anatomical abnormalities of the osteomeatal region are visualised, and mucosal disease of the hiatus semilunaris and early polyp disease, both inaccessible with a simple speculum, may be noted.

Next comes diagnostic imaging, undergoing many exciting developments at present, with great benefit to ENT practice as well as many other fields. Conventional sinus X-rays have always presented a twin problem. There is a 10% false negative rate for normal films on the one hand, and a much higher incidence of false positives with insignificant mucosal thickening on the other. High definition CT scanning (Fig 2) provides the solution. With sufficiently thin sections, the interior of every sinus may be demonstrated, together with the important antral ostium and frontonasal duct. The quality of the images rules out false negatives; the functional detail avoids confusing false positives. The radiation dose is

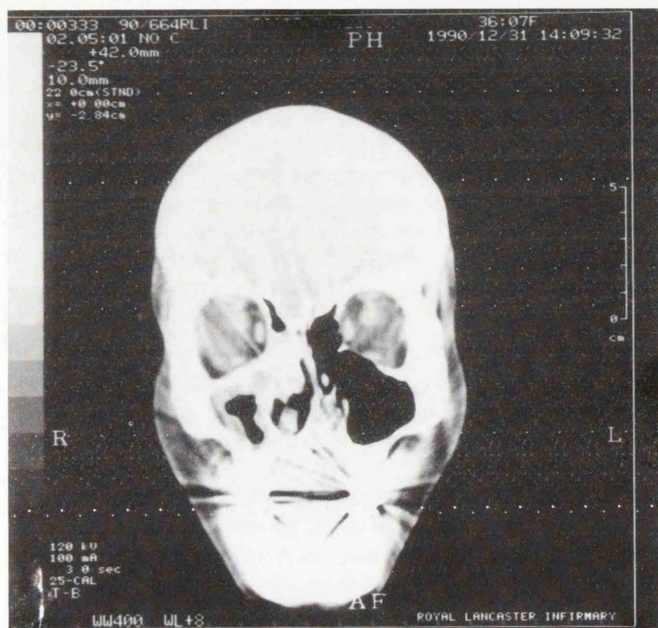


Fig 2

not excessive, nor is the procedure unpleasant. Cost is the only limiting factor.

Figure 2 shows one section from the scan of one of the author's patients, with a long history of right sided recurrent maxillary sinusitis, and a current bout which persisted obstinately despite chemotherapy and antral lavage. The causative ethmoidal disease is well visualised; the antrum *cannot* drain – compare the normal opposite side, and remember that, in health, the antral cilia will *always* propel secretions towards the antral ostium, and in no other direction. The satisfying drainage of mucus through an antrostomy fashioned surgically in the inferior meatus *only* occurs when the cilia are overloaded.

What are the indications for these excellent but expensive scans? In my view, where the patient's symptoms are of noninfective rhinitis only (blockage, clear mucoid or watery discharge, sneezing) and nasal endoscopy is normal, no imaging is required. Where examination shows evidence of chronic sinus disease, scans rather than X-rays should now be used to define the true extent of the problem, and to plan *functional* surgery. Where symptoms of purulent rhinorrhoea or facial pain raise the question of sinus disease, and endoscopy is negative, there is much to be said for scanning the patient to exclude the diagnosis. Figure 3 shows a section from the scans of a dental surgeon, who was convinced that his recurrent frontal headaches resulted from frontal sinusitis, although they were not accompanied by appropriate nasal symptoms. Here, the frontal sinuses are unequivocally normal. A well pneumatized, healthy ethmoidal bulla (arrow) is seen on the patient's right. The entire series showed equally healthy sinuses. Under these circumstances, the investigation is definitive, and unnecessary treatment is avoided.

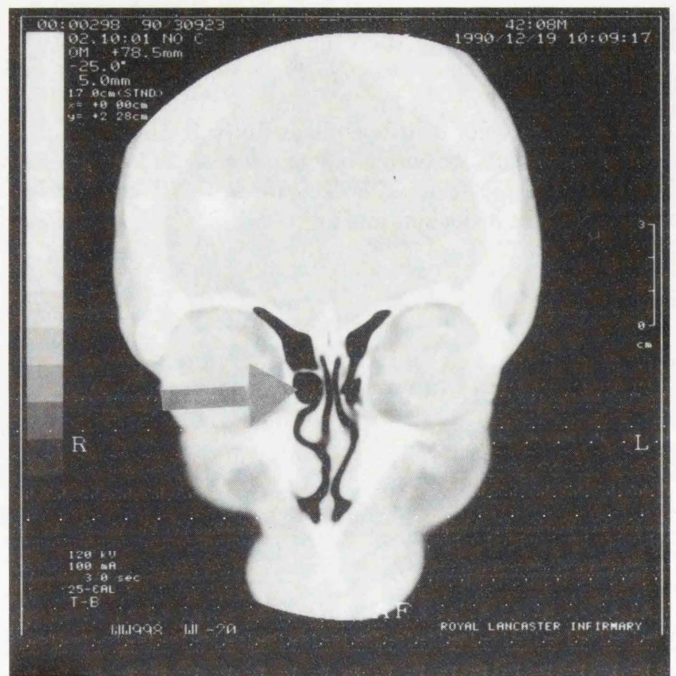


Fig 3

Where nasal polyp disease is present, the situation is more complex. All these patients have ethmoidal disease, for these cells are the origin of the polyps (with the exception of the rare antrochoanal variety). All are therefore predisposed to infection of all sinus groups, but many do not in fact develop sinusitis. I do not routinely scan those whose polyp disease appears to be uncomplicated – by which I mean that there are no complaints of purulent rhinorrhoea, head colds of ordinary duration excepted; no episodes of putative sinus pain; and no

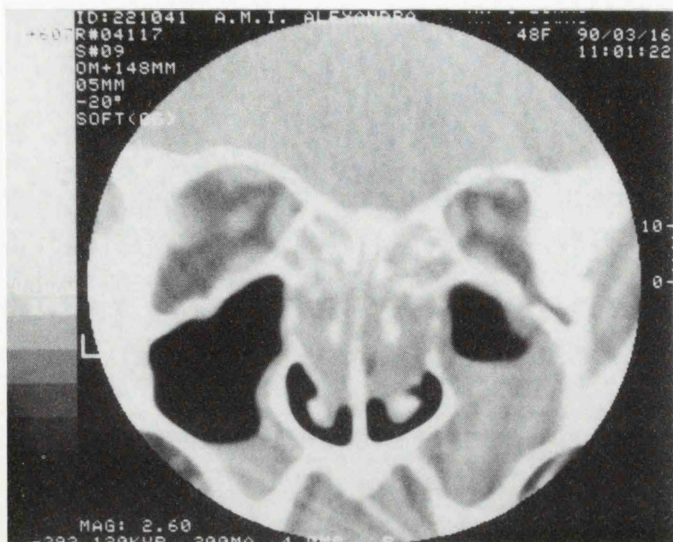


Fig 4

pus on nasal endoscopy. Many of these cases are suitable for medical therapy. Where there is clinical suspicion of coexisting infection of the sinuses, scanning is indicated before treatment is planned. Figure 4 shows a case of gross chronic bilateral ethmoidal disease. The patient had florid polyps, and had been waking at night to clear infected nasal and postnasal secretions for many years. Combined surgical and medical treatment was required.

Part II will deal with advances in treatment.

FURTHER READING

1. Stammberger H, Wolf G. Headaches and sinus disease: the endoscopic approach. *Annals of Otolaryngology and Rhinology* 1988; 97: 5, Part 2.
2. Lund V.J. Surgery of the ethmoids, past, present and future. *Journal of the Royal Society of Medicine* 1990; 83: 451-455.

Take one!



Simple once-a-day dosage

Adults: Tablets
200mg once a day

For severe or complicated infections:
2 x 200mg daily

Suprax

cefixime

Once-a-day simplicity in bronchitis

SUPRAX ABREVIATED PRESCRIBING INFORMATION

Presentation Rectangular, white, film-coated tablets with a break-line on each side and engraved "SI PRAX" on one side and "11200" on the other side. Each tablet contains 200mg of cefixime. Powder for Paediatric Oral Suspension. When reconstituted, each 5ml contains 100mg of cefixime and 2.5g saccharose. **Indications** Suprax is an orally active cephalosporin antibiotic for the treatment of acute upper and lower respiratory tract infections, otitis media and urinary tract infections. **Dosage** The usual course of treatment is 7-14 days. **Adults and children over 12 years (or over 50kg)** 200mg once daily. For severe or complicated infections, 2 x 200mg daily (in single or divided doses). **Children** 5mg/kg/day either once daily or as 2 divided doses. **Guidance:** 6 months to one year: 3.75 ml daily. 1 to 4 years: 5ml daily. 5 to 10 years: 10ml daily. 11 to 12 years: 15ml daily. (A double-ended spoon is supplied with the 37.5ml bottle to aid correct dosing of younger children). **Elderly** No dosage adjustment required. **Use in renal impairment** If creatinine clearance is less than 20ml/minute, do not exceed 200mg once daily. **Contra-indications** known hypersensitivity to cephalosporins. **Warnings and precautions** Use with caution in patients who have shown hypersensitivity to other drugs including penicillin. If allergic reaction occurs, stop Suprax therapy and substitute with alternative therapy. Overgrowth of clostridia may occur. The possibility of pseudomembranous colitis should be considered in patients who develop diarrhoea. Do not use in pregnancy or in nursing mothers unless considered essential. **Overdose** No experience to date. General supportive measures are recommended. **Side effects** Suprax is generally well tolerated. The most frequent side effects are diarrhoea and stool changes. Suprax should be discontinued if marked diarrhoea occurs. Pseudomembranous colitis has been reported. The majority of adverse reactions are mild and self-limiting and include other gastrointestinal disturbances, headache, dizziness, thrombocytopenia, leukopenia, eosinophilia, altered liver and renal function tests and hypersensitivity reactions. **Legal Category** POM. **Package quantities and basic NHS cost** Tablets: 200mg, bottles of 50 tablets (£1.28 a day at 200mg daily dosage). Powder for Paediatric Oral Suspension: bottles containing powder for preparation of 37.5ml (40, 100, 250ml (£10.95)). **Product Licence Numbers** Powder for Paediatric Oral Suspension: PL0095/0211. Tablets, 200mg: PL0095/0212 (Cyanamid of Great Britain Ltd). For full prescribing information see data sheet.



Lederle Laboratories, Cyanamid House, Fareham Road
Gosport, Hampshire PO13 0AS. Telephone (0329) 224000

*Suprax is a trademark

Date of Preparation: August 1990