

Extradural Haematoma: A Review

David Kelly MBChB,¹ Catriona Shenton MBChB, MRCS (ENT)²

¹ ACCS Trainee Year 2, Royal Preston Hospital ² Core Surgical Trainee Year 2, Neurosurgery Department, Royal Preston Hospital

INTRODUCTION

A bleed between the skull and dura mater is called an extradural or epidural haematoma (EDH)^{1,2} and is a type of intracranial haemorrhage. Extradural haematomas can compress the adjacent parenchyma, acutely increasing the intracranial pressure,³ resulting in a neurosurgical emergency.^{2,3} Early diagnosis and management of extradural haematomas is therefore essential to reduce associated morbidity and mortality.⁴ The commonest cause of extradural haematomas is trauma,^{1,2,5} although spontaneous extradural haematomas can also occur.^{6,7}

Here we present an overview of extradural haematomas to help clinicians to understand the presenting features, investigations and management.

ANATOMY

The central nervous system is covered by a membranous lining, the meninges. Three layers make up the intracranial meninges; from deep to superficial these are the pia mater, arachnoid mater and dura mater. The dura mater is the most superficial layer of the meninges and is also made up of three layers; the inner border cells layer, the middle meningeal layer and the outer endosteal layer.⁸

The outer endosteal layer adheres strongly to the inner surface of the calvaria, also forming the periosteal lining of the skull inner surface.⁸ No communication exists between the endosteal layer and the spinal cord dura; the outer skull periosteum and endosteal layer are continuous at the skull foraminae. At the cranial sutures, the endosteal layer and the suture ligaments are continuous.⁸ Extradural haematomas are therefore unable to cross the sutures of the skull.⁵

Nerves, lymphatic vessels and blood vessels are situated between the outer endosteal layer of the dura mater and the inner surface of the skull.⁸ Extradural haematomas therefore occur between the dura mater endosteal layer and the skull.⁵ Different vessels are responsible for supplying different anatomical regions of the dura; these vessels run in the endosteal layer.⁸

The middle meningeal artery is the most important arterial supply of the dura mater, arising most commonly from the maxillary artery which branches off the external carotid artery. Rarely, it can arise from internal carotid artery branches or, rarer still, the stapedia artery. The middle meningeal artery passes through the foramen spinosum or, less commonly, the petrosphenoid fissure, to enter the cranial cavity, before running along the squamous temporal bone in an anterolateral groove.⁸

The middle meningeal artery has three branches; a posterior branch, a middle branch and an anterior branch. Each branch has a separate intracranial course; the posterior branch runs along the temporal lobe inferior border, the middle branch is situated at the lateral sulcus and the anterior branch travels behind the coronal suture.⁸ The middle branch of the middle meningeal artery can originate from either the anterior or posterior branch or from both branches. The Adachi scoring system is applicable to the origin of the middle branch of the middle meningeal artery; anterior branch origin is Adachi type I, posterior branch origin is Adachi type II and

origin from both the anterior and posterior branches is Adachi type III.⁸

The dura in the anterior cranial fossa is supplied by a middle meningeal artery branch and anterior meningeal branches of the internal carotid, anterior ethmoidal and posterior ethmoidal arteries.⁸

The dura in the middle cranial fossa is supplied by a lacrimal artery branch, an ascending pharyngeal artery branch and accessory meningeal branch and middle meningeal branch of the maxillary artery.⁸ The dura in the posterior cranial fossa is supplied by vertebral artery posterior meningeal branches, occipital artery meningeal branches and ascending pharyngeal artery small branches.⁸

Extradural haematomas usually occur secondary to arterial injury.^{1,5,9} The most common locations for extradural haematomas are the temporoparietal or temporal regions,¹⁰ with the middle meningeal artery the most commonly injured vessel resulting in extradural haematoma at this site.^{3,11,12,13} Trauma to the frontal region results in injury to the anterior ethmoidal artery.³

Depending on the haematoma site, the source of the haemorrhage can also be venous, usually from the Diploic vein, or from a venous sinus,^{3,5,12} usually the lateral or sagittal.³ Bleeding from the Diploic vein or lateral/sagittal sinus usually causes a temporal or temporoparietal haematoma.³

The majority of extradural haematomas in the posterior fossa are venous, occurring secondary to fractures of the occipital bone with consequent sigmoid or transverse sinus injury.³ Venous bleeds can also arise from arachnoid granulation rupture or emissary veins.^{9,12}

In paediatric acute traumatic extradural haematoma, anatomical regions involved include the temporoparietal region, frontal region and parietal region, with involvement of the posterior fossa occurring less frequently.⁴ Extradural haematomas secondary to venous injury are more common in paediatric patients.^{4,5}

AETIOLOGY

The commonest cause of acute extradural haematoma is trauma,^{1,2,5} with fractures of the skull damaging a meningeal artery the most common aetiology.^{2,6,11,14} In adults, the most common causes of trauma are road traffic accidents, falls, industrial accidents, sport injuries and assault.^{4,10,12} In children, traumatic extradural haematomas can occur after minimal impact with common causes including falls and road traffic accidents.^{4,12} Associated skull fractures appear to be more common in adult than paediatric traumatic extradural haematomas.⁴

Spontaneous extradural haematomas can occur secondary to dura mater arteriovascular malformations, infections of adjacent tissue,^{6,7} coagulopathic disorders or extradural metastasis.⁷

Infective causes of spontaneous extradural haematoma include sinusitis, otitis and orbital cellulitis.^{6,7} It is thought that meningeal vessel walls are weakened by arteritis, resulting in development of extradural haematoma.^{6,7} Alternatively, the skull inner table and the dura mater can become separated either by pus or air accumulating in the extradural space,⁶ resulting in slow haemorrhage of minor vessels.¹⁵ Such air

accumulation occurs after passing through an infection related defect in the paranasal sinuses, mastoid air cells or middle ear.^{6,15}

Traumatic extradural haematomas can also be iatrogenic; iatrogenic causes include ventricular procedures, post-operative hydrocephalus secondary to surgery on posterior fossa tumours or neurosurgical procedures resulting in collapse of brain tissue.⁶

EPIDEMIOLOGY

Approximately 1-2% of head traumas result in extradural haematomas.^{6,16} Spontaneous extradural haematomas are rarer.⁷ The highest incidence of acute extradural haematomas is amongst 30 year olds, with a predisposition for the male sex.^{2,10} It is less common in the elderly and younger population as the dura is more closely adhered to the inner calvarium in these age groups.^{2,4,9}

In paediatric extradural haematomas, children aged 11 or older are more commonly affected than infants younger than 12 months and boys are more commonly affected than girls.⁴

CLINICAL PRESENTATION

Presentation can vary depending on the size, site and age of the extradural haematoma. Extradural haematomas secondary to arterial injury present more acutely than those secondary to venous injury.⁵ The textbook presentation of acute traumatic extradural haematoma is transient loss of consciousness, a lucid interval then a rapid decrease in Glasgow Coma Score (GCS).^{5,10} The rapid increase in the size of the haematoma is thought responsible for this "talk and die" presentation of extradural haematomas, with clinical deterioration seen more often when the haematoma size increases by 1cm or more.³ Although classical, these symptoms are only seen in less than half of patients.¹⁰

The symptoms in spontaneous extradural haematoma are more variable, depending on the underlying cause. Spontaneous extradural haematomas due to a vascular malformation can present with hemiparesis, sudden headache and progressively deteriorating GCS.⁶ Dural vascular malformations themselves can present with hydrocephalus, motor weakness, headaches, altered vision, seizures or intracranial bruits.⁶ Spontaneous extradural haematomas due to infection can present with asymmetrical pupils, reduced GCS and extensor plantar reflexes.⁶ Spontaneous extradural haematomas associated with coagulopathies can present with vomiting, altered sensorium and headache followed by hemiparesis and reduced GCS.⁷

The most common presenting complaints in acute paediatric extradural haematomas are altered sensorium, headache, vomiting and a lucid interval, with other symptoms including focal neurological deficit, dilated pupils, hemiparesis and seizures.⁴

DIFFERENTIAL DIAGNOSIS

Differentials which need to be excluded following traumatic head injury include other intracranial haemorrhages. These can be subdural, subarachnoid or intracerebral.⁵ Differentials for spontaneous extradural haematoma secondary to adjacent infection include brain abscess, extradural or subdural empyema and cortical thrombophlebitis.⁶

INVESTIGATIONS

Non-contrast computerised tomography (CT) of the brain is the radiological investigation of choice in diagnosis and monitoring extradural haematomas in all age groups^{3,4,12} due to its ready availability.⁵ It can also show complications and help to identify the underlying aetiology.⁵ For example, CT and CT venography (CTV) can be used to demonstrate venous sinus injury, shown as sinus displacement, compression or extravasation.⁹

The typical CT appearance of an extradural haematoma is an extra-axial biconvex lesion which is well defined.⁵ The appearance of haematomas on CT are influenced by how much the haemorrhage attenuates x-rays, with lesion density determined by the protein content, haemoglobin fraction, haematocrit and amount of retraction of the blood clot.⁵ Haematomas of differing ages therefore have varying appearances.⁵

In general, intracranial bleeds or haematomas have five stages; a hyperacute haemorrhage is less than 12 hours old, acute is between 12 hours and 48 hours, early subacute is 48 hours to 7 days, subacute is 8 days to 28 days and chronic is over 28 days.⁵

Haemorrhages in the hyperacute phase can be difficult to visualise on CT as the brain parenchyma has the same density as the hyperacute haemorrhage due to the presence of serum alongside platelets, white blood cells and red blood cells.⁵ The clot density increases rapidly in the acute and early subacute phase due to serum component extrusion and retraction of the blood clot. Such lesions have a hyperdense appearance on CT as the globin concentration is increasing,^{5,13} with extrusion of serum and vasogenic oedema resulting in a surrounding hypodense rim.⁵ The clot density reduces during the late subacute phase due to globin protein proteolysis and lysis of red blood cells; this is seen as an isodense lesion on CT.⁵ Phagocytization in the chronic phase results in resolution of a hypodense haematoma on CT. A hypodense defect in the brain parenchyma can persist, with occasional hyperdense calcifications, focal atrophy or sulci enlargement.⁵

The "swirl sign" on CT imaging is attributed to extradural haematomas, although it is rarely seen. It consists of a hyperacute and an active component. The hyperacute component demonstrates active bleeding and is seen as a circular circumscribed hypodense or isodense lesion compared to the rest of the haematoma.¹³ The active component reflects a hyperdense haematoma. It therefore suggests that the extradural haematoma is increasing in size due to active bleeding.¹³

Magnetic resonance imaging (MRI) is considered to be the most sensitive imaging technique for all intracranial bleeds; it tends to be used when neurological findings do not correlate with CT images.⁵

The magnetic properties of each of the breakdown products of haematomas vary as the iron they contain is oxidised to varying degrees. T1 and T2 weighted imaging can therefore be used to estimate the hemorrhage age.⁵

Carotid angiography shows extradural haematomas as a space occupying lesion with no vascularity and can be used to demonstrate congenital dura mater arteriovenous malformations.⁶

MANAGEMENT

Extradural haematomas need managing in a neurosurgical centre³ and management can be conservative or surgical,¹⁰

regardless of the underlying aetiology^{6,7} or source of bleed.⁹ Haematoma volume, thickness, location, amount of midline shift, GCS and patient progress are all factors which influence the decision regarding surgical or conservative management.^{3,9,12}

Some studies suggest that presenting GCS and volume of the extradural haematoma on CT imaging are the most relevant indicators for surgical management,^{3,9} with emergency surgical evacuation indicated for deterioration in neurology or large volume haematomas.¹¹ Guidelines from The British Trauma Foundation recommend that surgical evacuation should occur for any extradural haematoma exceeding 30cm³ regardless of the GCS.³

Indications for conservative management include a haematoma with a volume below 30cm³ and depth below 15mm, with midline shift less than 5mm where there are no focal neurological deficits and the GCS is higher than eight.^{3,12} Conservative management in these patients is successful as accommodation of the haematoma by the brain is possible until it has been reabsorbed.¹² Indicators for conservative management of venous sinus-related extradural haematomas include absence of neurological abnormalities, small haematoma volume (less than 10ml on average) and small mass effect.⁹

Patients with a posterior fossa or supratentorial extradural haematoma and GCS less than nine with focal neurological deficits, extradural haematoma volume over 30cm³ (in posterior fossa) or over 60cm³ (in supratentorial haematomas) or more than 5mm of midline shift need urgent surgical evacuation. Supratentorial haematomas with none of the above can be managed with half hourly neuro-observations and vital signs.³

A key component of managing posterior fossa extradural haematomas is managing hydrocephalus.³ Posterior fossa haematomas with none of the above features, but with hydrocephalus on CT imaging, should undergo ventriculostomy with or without insertion of ventriculo-peritoneal shunt followed by half hourly neuro-observations and vital signs. If hydrocephalus is absent, the patient can be managed with half hourly neuro-observations and vital signs.³

For any patient undergoing neuro-observations and vital signs, a reduction in GCS in less than six hours is an indication for surgical evacuation. If, after six hours, there is no reduction in GCS, repeat CT of the brain should be performed by 48 hours, depending on the patient's clinical state. Surgery is indicated if serial imaging shows an increase in the volume of the extradural haematoma; patients can be managed conservatively if there is no change in the volume of the extradural haematoma.³

The risk of haematoma expansion is higher when bleeding is in the temporal region; because of this, the surgical threshold should be lower in these patients.³

Conservative management

Conservative management consists of close monitoring and serial CT imaging within six to eight hours of the traumatic injury to assess lesion stability.^{3,9}

Surgical management

Craniotomy/craniectomy and clot evacuation is the main surgical management of extradural haematomas.^{9,14} Craniotomy consists of excising a bony window from the skull, providing good exposure of the intracranial cavity. The clot is evacuated and the bony flap that has been removed is then used to close the skull window; the bony flap is secured

with sutures or titanium screws and plates. The bony flap is considered fully healed when mature bone has grown, incorporating the flap into the skull.¹⁴

An alternative but less commonly utilised surgical technique is burrhole evacuation. Burrhole evacuation consists of drilling 1.5-2cm holes into the calvarium and draining the underlying clot. No bone requires replacement, although artificial burrhole covers exist.¹⁴

Embolisation of the middle meningeal artery is a relatively novel endovascular treatment option for acute extradural haematomas.¹¹

Surgical management of venous sinus related extradural haematomas is complicated by the associated risk of damage to the sinus and the fact that controlling bleeding from the sinus can be difficult due to poor visibility. An alternative surgical technique for superior sagittal sinus related extradural haematomas is a strip craniotomy, which involves multiple craniotomies, with a bone strip left in situ over the sinus. Progressive resection of the clot from the edge of the clot whilst suturing the residual bone and dura mater is then performed. The superior sagittal sinus is not primarily repaired and any clot which is directly over the sinus is left undisturbed.⁹

Paediatric extradural haematoma management

Deciding on conservative versus surgical management in paediatric traumatic extradural haematoma is complicated by the lack of management guidelines.⁴ So far, a combination of radiological and clinical features have been used to decide on surgical management. These features include: extradural haematoma bigger than 20ml with deterioration in GCS or loss of consciousness; haematoma volume of 30ml regardless of neurological status; haematoma volume of 20ml in a critical area; deterioration in GCS with a midline shift over 0.5cm; or increase in haematoma volume.⁴ Conservative management in paediatric extradural haematomas consists of monitoring vital signs, neurology and GCS.⁴ Surgical management in paediatric traumatic extradural haematomas consists of craniotomy and clot evacuation under general anaesthetic⁴

Prognosis

A variety of factors influence extradural haematoma morbidity and mortality but both morbidity and mortality can be significant, with traumatic extradural haematoma mortality rates between 1.2 and 33%.^{2,3,9,16} Both morbidity and mortality are reduced by early treatment.^{3,16} Outcomes in both paediatric and adult extradural haematomas strongly correlate with associated injuries to the brain parenchyma and GCS score, with low admission GCS associated with high mortality rates in surgically managed traumatic extradural haematomas in adults.^{2,4,10}

It has been suggested that a higher mortality rate is associated with increasing age.^{10,16} The intracranial space between the brain and skull is increased by age-related reduction in brain mass; this extra space may enable a larger sized haematoma to develop before the patient displays neurological signs.¹⁶

A "swirl sign" on CT imaging, indicating active bleeding within an extradural haematoma that is increasing in size, is associated with higher rates of mortality and morbidity.¹³ Presence of a skull fracture has also been associated with reduced mortality, with correlation seen between faster extradural haematoma resolution and the presence of a

skull fracture, possibly due to transfer of the haemorrhagic material via the skull fracture.^{3,10} In a study of venous sinus-related extradural haematomas, at follow up, the Glasgow outcome score was high, reflecting good outcomes in venous sinus-related extradural haematomas with conservative or surgical management.⁹

According to a previous study of 170 traumatic paediatric extradural haematomas, a post-operative mortality rate of 8% was seen.⁴ Suggested poor prognostic factors include increasing age (above the age of 10), reduced GCS, time from reduced GCS to surgery, injury to the brain and unreactive pupils.⁴ Site of the haematoma also appears to be relevant, with convexity haematomas associated with poorer prognosis than frontal haematomas.⁴

COMPLICATIONS

Complications of extradural haematoma include damage to brain parenchyma, midline shift, herniation and death.^{2,5} Due to limited space in the posterior fossa, extradural haematomas can cause obstructive hydrocephalus, causing clinical deterioration. This also means that a posterior fossa extradural haematoma as small as 10ml can result in the same amount of brain compression and amount of midline shift seen in a 30ml supratentorial extradural haematoma.³

Postoperative complications in traumatic extradural haematoma include neurological complications, bleeding, haematoma formation, pulmonary embolism, deep vein thrombosis, renal complications, cardiac complications and pulmonary complications.² Following craniotomy, if a bone flap does not heal sufficiently, the craniotomy site can be a site of weakness and therefore at risk of traumatic injury.¹⁴ Where extradural haematoma is secondary to venous sinus injury, surgical management is complicated by the risk of bleeding, infarction and venous air embolism.⁹

Paediatric traumatic extradural haematomas can result in epilepsy, especially where intradural injury co-exists.⁴

CONCLUSION

Extradural haematomas most commonly occur secondary to traumatic head injury. Patients may therefore present to both primary and secondary care either at the time of injury or much later.

Extradural haematomas can acutely raise the intracranial pressure, resulting in a neurosurgical emergency. An awareness and understanding of the varying presenting features and relevant investigations is therefore essential amongst all clinicians who may encounter patients presenting with a head injury, as early diagnosis and management of extradural haematomas reduces associated morbidity and mortality.

Correspondence to:

David Kelly, email: dkanaesthetic@gmail.com
Critical Care Unit, Royal Preston Hospital,
Sharoe Green Lane, Fulwood, Preston PR2 9HT

REFERENCES

1. Naidech AM. Intracranial hemorrhage. *Am J Respir Crit Care Med* 2011;184(9):988-1006. Available from: <https://doi.org/10.1164/rccm.201103-0475CI>
2. Bir SC, Maiti TK, Ambekar S, Nanda A. Incidence, hospital costs and in-hospital mortality rates of epidural hematoma in the United States. *Clin Neurol Neurosurg* 2015;138:99-103. Available from: <https://doi.org/10.1016/j.clineuro.2015.07.021>

3. Zakaria Z, Kaliaperumal C, Karr G, O'Sullivan M, Marks C. Extradural haematoma--to evacuate or not? Revisiting treatment guidelines. *Clin Neurol Neurosurg* 2013;115(8):1201-1205. Available from: <https://doi.org/10.1016/j.clineuro.2013.05.012>
4. Chowdhury SN, Islam KM, Mahmood E, Hossain SK. Extradural haematoma in children: surgical experiences and prospective analysis of 170 cases. *Turk Neurosurg* 2012;22(1):39-43. Available from: <https://doi.org/10.5137/1019-5149.JTN.4550-11.1>
5. Hüisman TA. Intracranial hemorrhage: ultrasound, CT and MRI findings. *Eur Radiol* 2005;15(3):434-440. Available from: <https://doi.org/10.1007/s00330-004-2615-7>
6. Sanchis JF, Orozco M, Cabanes J. Spontaneous extradural haematomas. *J Neurol, Neurosurg Psychiatry* 1975;38:577-580. Available from: <https://doi.org/10.1136/jnnp.38.6.577>
7. Khan KA, Chhabra S, Sharma S, Purohit D. Spontaneous extradural hematoma: a rare entity. *Br J Neurosurg* 2020;34(1):86-88. Available from: <https://doi.org/10.1080/02688697.2017.1409882>
8. Adeeb N, Mortazavi MM, Tubbs RS, Cohen-Gadol AA. The cranial dura mater: a review of its history, embryology, and anatomy. *Childs Nerv Syst* 2012;28:827-837. Available from: <https://doi.org/10.1007/s00381-012-1744-6>
9. Parker SL, Kabani AA, Conner CR, et al. Management of venous sinus-related epidural hematomas. *World Neurosurg* 2020;138:e241-e250. Available from: <https://doi.org/10.1016/j.wneu.2020.02.089>
10. Ruff LM, Mendelow AD, Lecky FE. Improving mortality after extradural haematoma in England and Wales. *Br J Neurosurg*. 2013;27:19-23. Available from: <https://doi.org/10.3109/02688697.2012.709555>
11. Zussman BM, Goldschmidt E, Faraji AH, Salvetti DJ, Jankowitz BT. Middle meningeal artery embolization for the treatment of an expanding epidural hematoma. *World Neurosurg* 2019;128:284-286. Available from: <https://doi.org/10.1016/j.wneu.2019.05.084>
12. Charcos IB, Wong TW, Larsen BR, et al. Location of traumatic cranial epidural hematoma correlates with the source of hemorrhage: a 12-year surgical review. *World Neurosurgery*. 2021;152:e138-143. Available from: <https://doi.org/10.1016/j.wneu.2021.05.052>
13. Gupta VK, Seth A. "Swirl sign" in extradural hematoma. *World Neurosurg*. 2019;121:95-96. Available from: <https://doi.org/10.1016/j.wneu.2018.10.010>
14. Davis G, Marion DW, Le Roux P, Laws ER, McCrory P. Clinics in neurology and neurosurgery—extradural and subdural haematoma. *Br J Sports Med*. 2010;44:1139-1143. Available from: <https://doi.org/10.1136/bjism.2008.048215>
15. Gordon AC. Extradural haematoma with sinusitis. *J R Soc Med*. 2002;95(2):110-112. Available from: <https://doi.org/10.1258/jrsm.95.2.110-a>
16. Soon WC, Marcus H, Wilson M. Traumatic acute extradural haematoma – Indications for surgery revisited. *Br J Neurosurg*. 2016;30(2):233-234. Available from: <https://doi.org/10.3109/02688697.2015.1119237>

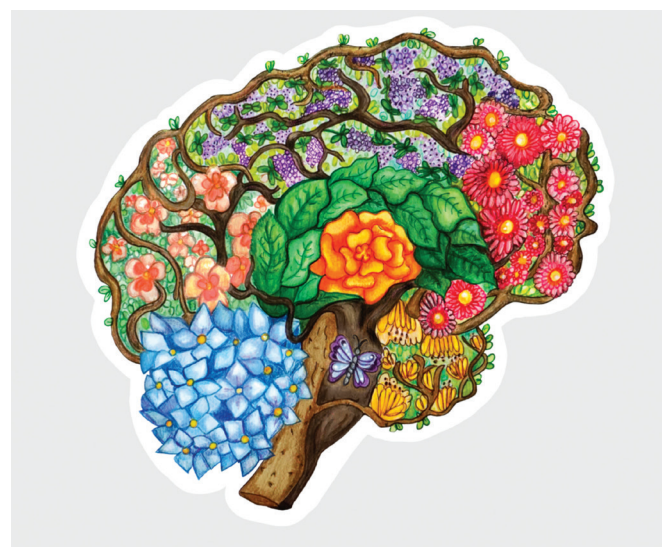


Illustration by Zuzanna Nowinka (Medical Student)