

Laser-Induced Retinal Injury in Children: A Public Health Risk

Adam Geressu, MD, Dr. Jayaprakash Patil, MBBS, MS, FRCS OPHTH

INTRODUCTION

Laser pointers are battery-powered handheld devices that use a laser diode to emit a laser beam for pointing at objects; these laser devices have also been marketed to and used by children as “toys”. Lasers are commonly thought of as causing minimal harm to vision. However, there has been an increasing number of children suffering from retinal injury as a result of laser pointers and laser toys.¹ Historically, laser-induced retinal injuries have been reported as an occupational hazard mostly among people working in the military, industrial, or hospital sector.² Due to an increase in global demand for high-power laser devices; cheaper and more accessible options have become more readily available for public use. This has led to laser pointers and laser toys being purchased online and imported from countries with little to no safety regulations which often prove to be problematic. This increased demand along with potentially harmful effects on vision has led to public and medical interest in laser-induced retinal injuries.^{3,4}

Laser-induced injury to the retina occurs when powerful lasers are directed to the eye from a short distance resulting in macular inflammation with associated edema. The macular inflammation and edema may resolve over time, but permanent photoreceptor loss and retinal pigment epithelium damage can develop, eventually resulting in decreased central vision.⁵ There have been cases of patients developing retinal haemorrhage immediately following laser exposure.²

Laser-induced retinal injury is based on a multitude of factors. This includes both patient-related (eg: pupil size, refractive status, degree of retinal pigmentation, proximity of incident laser beam to the fovea) and laser-related factors (eg: wavelength, pulsatile duration, and energy of the laser beam).⁶ Laser devices either emit red coloured light (wavelengths between 630 and 670 nm), green coloured light (532 nm) or blue coloured light (about 445 nm). Green coloured light is known to cause damage to the retinal pigment epithelium and outer retina in a short duration of time.⁷ In addition, the labelling of the power output of a laser pointer may be different from the device’s actual specifications. Recent studies have shown that, after measuring the power of 122 laser pointers labeled as 1 to 5 megawatts (mW), it was found that 90% of green laser pointers and 44% of red laser pointers tested had power outputs >5 mW.⁸ Most laser pointers have a power output <5mW, which is not considered harmful to the eye due to the blink reflex and aversion responses.^{9,10} However, prolonged viewing of a laser pointer or laser toy beam for more than ten seconds is potentially harmful, while accidental exposure is safe because it is usually terminated in less than 0.25 second.^{11,12} All these factors are important causes of laser-induced injury to the eye and can potentially lead to blindness.⁹

The objective of this paper is to draw attention to the potential hazard of laser pointers/toys and to raise awareness of the public health risk to children. We report nine children with retinal injury caused by laser pointer and laser toy exposure. In addition, it is important for clinicians to recognise and be cognisant of the presentation of laser-induced retinal injury.

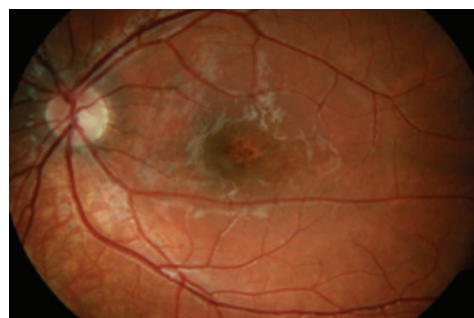
CASE SERIES

Case 1

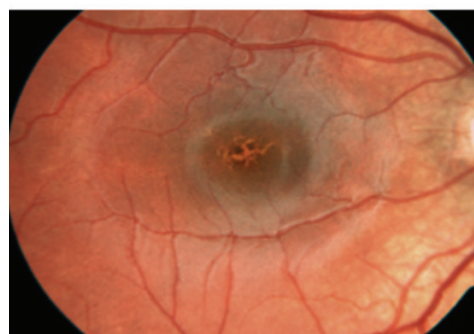A nine year old girl presented with a history of decreased vision in her left eye. Her mother brought her to the ophthalmology clinic after her daughter had problems seeing the board at school. The patient’s mother mentioned purchasing a laser pointer from Egypt which her daughter would constantly play with at home. On examination, the best corrected vision in her left eye was 6/18 and 6/6 in her right eye. On clinical examination the patient had central scotoma on closing her left eye. Fundoscopy revealed she had left macular atrophic lesion with scarring, while right macula is healthy (Figure 1). She had a follow-up three month appointment with the orthoptist and a twelve month appointment with the ophthalmologist after the initial consultation.

Case 2

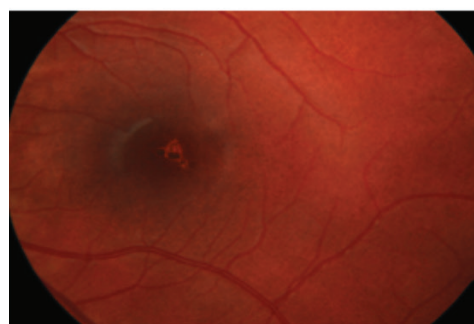
A seven year old boy was referred to the ophthalmology clinic from an optician for having pigmentary changes in his right eye. He had no family history or features of retinitis pigmentosa. He presented as visually asymptomatic. He had



Patient 1



Patient 2



Patient 3

Figure 1: Fundoscopy findings in patients presented in cases 1-3.

a history of playing with a toy laser which was purchased from Spain. On assessment his best corrected visual acuity was 6/9 in right eye and 6/5 in left eye. On fundoscopic examination he had hyperpigmented changes in his right eye that were not seen before (Figure 1). He had an eleven month follow-up after the initial consultation.

Case 3

A ten year old boy presented to the ophthalmology clinic after having difficulty viewing the board at school. On assessment his best corrected visual acuity is 6/6 in his left eye and 6/5 in right eye. There was full colour vision on Ishihara colour vision testing. On visual examination the patient appeared to have micropsia. Fundoscopy was normal apart from small vitreous floaters in inferior region of his left eye (Figure 1). On OCT (optical coherence tomography) there were subtle changes in the inner retinal layers and photoreceptors in the left eye, sub-foveal, while these changes were not seen in right eye. He had a seven month follow-up after the initial consultation.

Case 4

A 12 year old boy presented with a history of blurry vision in both his eyes. He also complained of difficulty with near vision. He had a medical history of ADHD, moderate learning difficulties and anger issues. His mother reported a history of her son playing with a laser pointer. On examination the best corrected vision was 6/9 in both eyes. On further examination he had bilateral multiple macular atrophic lesions. OCT showed localised sub-foveal hyper-reflective areas of atrophy involving the outer retinal layers, photoreceptors and retinal pigment epithelium to some extent (Figure 2a and 2b). The rest of his ocular examination was unremarkable, except for fine pupillary iris strands. He had a follow-up nine months after the initial consultation.

Case 5

An 11 year old boy was referred to the ophthalmology clinic due to macula pigmentary changes in right eye. His father reported that his son had a history of playing with a toy laser at home. He was visually asymptomatic. On examination, the best corrected vision was 6/12 in right eye and 6/9 in left eye. Fundoscopy revealed retinal epithelial pigment disturbances in the macula of his right eye, while his left macula was unremarkable. He had a follow-up six months after the initial consultation.

Case 6

A 12 year old boy was referred to the ophthalmology clinic after having decreased vision in his left eye. He had a history of shining a toy laser in his left eye. His parents purchased the toy laser two months prior to his initial presentation. On examination, the best corrected vision was 6/6 in right eye and 6/60 in left eye. One year prior to his initial assessment he had 6/6 vision in both eyes. On further examination there was scarring and bleeding in the macula of the left eye. He had a follow-up 12 months after the initial consultation.

Case 7

A 13 year old boy presented after having difficulty writing small letters. He lived in a foster home and had a history of ADHD. He reported purchasing a powerful laser gun online four years prior to his initial presentation. He admitted to shining the laser gun in his eyes. On examination, the best corrected vision was 6/36 in right eye and 6/9 in left eye. On visual examination there was a low degree of hypermetropia noted. Fundoscopy showed normal optic discs. On further examination there was a macular burn seen in both eyes with retinal pigment epithelium changes. He had a follow-up 12 months after initial consultation.

Case 8

A six year old boy was referred from the optician to the ophthalmology clinic for further testing because he had a cracked appearance of his right macula. He presented with a history of decreased vision in his right eye. He admitted to playing with a toy laser. He had no history of sun gazing or any previous infections/inflammatory conditions affecting the back eye. On examination, the best corrected vision was 6/9 in right eye and 6/6 in left eye. On further examination there was an area of retinal pigment epithelium atrophy in his right macula. He had a follow-up 12 months after initial consultation.

Case 9

A ten year old boy presented to the clinic after seeing a white blob in his central vision along with flashing lights in his left eye. He had no blurry vision or decrease in vision. He has a history of playing with a toy laser purchased in Egypt. On examination, the best corrected vision was 6/7.5 in right eye and 6/5 in left eye. Fundoscopy shows three fine drusen in the inferior macula of his right eye and hypopigmented macular

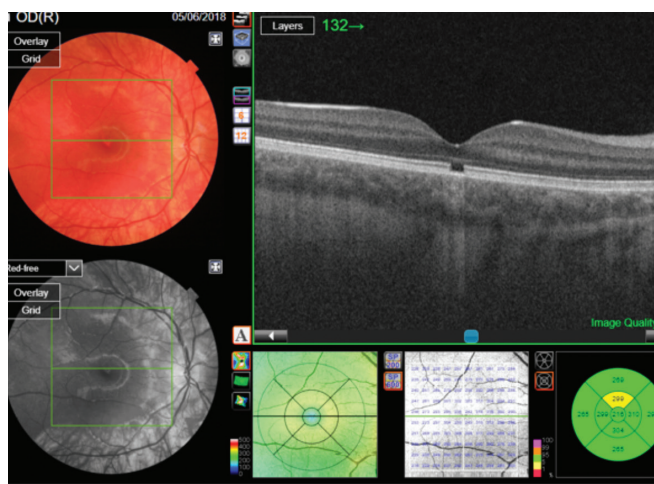


Figure 2a: OCT finding of right eye in patient presented in case 4.

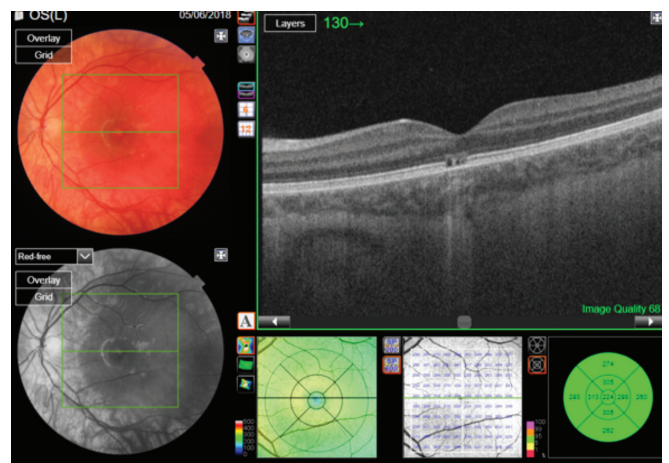


Figure 2b: OCT finding of left eye in patient presented in case 4.

changes at level of retinal pigment epithelium in his left eye, there was no subretinal fluid or haemorrhagic changes in either eye. He had a follow-up 12 months after initial consultation.

DISCUSSION

In this paper we describe nine cases of laser-induced retinal injury among nine different children within a 6-year period, the youngest of which was only 6 years of age. All these children with retinal injuries occurred at a single hospital trust. A summary of all nine cases can be found in Table 1.

Our case series demonstrates the importance of obtaining a thorough examination of children presenting with decreased vision or vision loss in one or both eyes. This examination should include a history of laser exposure, presenting symptoms, physical examination and funduscopy.¹⁰ If a patient presents with decreased vision and their history demonstrates an exposure to laser pointers or laser toys, the child should be referred to an ophthalmologist for full ophthalmologic workup including optical coherence tomography (OCT).¹³ Once diagnosed, treatment of laser-induced retinal injury is mainly limited to systemic corticosteroids, which has shown mixed results. However, corticosteroids have been used in experimental animal models of various laser retinal injuries with positive outcomes.⁶

Due to the potential harm of laser pointers and laser toys, certain safeguards have been introduced to protect consumers (such as the FDA safety notification in the US and BS EN 60825-1:2014 in the UK) (17). The British Standard set out 8 classes of laser products to help classify lasers by potential risk of adverse health effects, where the higher the class number, the greater the laser radiation. For safety it is recommended that a laser pointer should be no greater than a Class 2 laser product.⁷ Laser pointers sold in the United States are required to have an output power less than 5 mW.¹⁰ While in Great Britain, general use of Class IIIa lasers are banned. Keeping within these safety guidelines have prevented unsafe laser pointers and laser toys being sold within Great Britain.¹⁵

CONCLUSION

We highlight how accidental retinal injury among children due to laser pointer/toy exposure represents a serious, but preventable, public health issue. With improvement in technology, hand-held laser devices are becoming increasingly powerful and available via online outlets. These laser devices often do not conform to EU or British Safety Standards (BS EN 60825-1:2014), making the regulation of such devices difficult. We advise that laser devices, whether they are ‘toys’ or intended as laser pointers, are only purchased from stores and countries where laser safety specifications are upheld.

To further reduce laser-induced retinal injury especially in children we have made some recommendations. Firstly, parents and teachers should be aware of this emerging public health issue and educate children about the potential dangers of laser pointers and laser toys. The Government should also raise public awareness by funding public health campaigns to educate and prevent people from buying unregulated laser products for themselves or their children. Furthermore, laws should be created and enforced to prevent the sale and use

of these devices from countries that don’t uphold appropriate laser safety standards. Finally, at the clinical level, clinicians should be aware of the history and presentation of laser-induced retinal injury to prevent delaying diagnosis and improve health outcomes in their patients.

REFERENCES

1. Linton E., Walkden A., Steeples L., Bhargava A., Williams C., Bailey C., Quhill F.M. and Kelly S.P. Retinal burns from laser pointers: a risk in children with behavioural problems. *Eye* 2018;33(3):492-504.
2. Zhang L., Zheng A., Nie H. et al. Laser-Induced Photocopy Phenocopies Macular Dystrophy. *Ophthalmic Genetics* 2016;37(1):59-67.
3. Houston S. Aircrew exposure to handheld laser pointers: the potential for retinal damage. *Aviation Space and Environment Medicine*. 2011; 82: 921–922.
4. Turaka K., Bryan J.S., Gordon A.J., Reddy R., Kwong H.M. Jr., Sell C.H. Laser pointer induced macular damage: case report and mini review. *International Ophthalmology*. 2012;32(3):293-297
5. Abdelkader E. Accidental macular injury with class IVb laser outside the medical settings. *Saudi Journal of Ophthalmology* 2016;30(4):253-256.
6. Barkana Y., Belkin M. Laser eye injuries. *Survey of Ophthalmology*. 2000;44(6):459–478.
7. Laser radiation: safety advice [Internet]. GOV.UK. 2021 [cited 2021 Jan 17]; Available from: <https://www.gov.uk/government/publications/laser-radiation-safety-advice/laserradiation-safety-advice#laser-pointers-or-laser-pens>.
8. Hadler J., Tobares E., Dowell M. Random testing reveals excessive power in commercial laser pointers. *Journal of Laser Applications*. 2013;(25):032007
9. Birtel J., Harmening W., Krohne T., Holz F., Charbel I.P., Herrmann P. Retinal Injury Following Laser Pointer Exposure. *Deutsches Aertzteblatt International*. 2017;114(49): 831-837.
10. Mainster M.A., Stuck B.E., Brown J. Jr. Assessment of alleged retinal laser injuries. *Archives of Ophthalmology*. 2004;122(8):1210–1217.
11. Robertson D.M., Lim T.H., Salomao D.R., Link T.P., Rowe R.L., McLaren J.W. Laser pointers and the human eye: a clinicopathologic study. *Arch Ophthalmol*.2000;118(12):1686-1691.
12. Sliney D.H, Dennis J.E. Safety concerns about laser pointers. *Journal of Laser Applications*.1994;(6):159-164.
13. Marshall J. The safety of laser pointers: myths and realities. *British Journal of Ophthalmology* 1998;82(11):1335–1338.
14. Raouf N., Chan T.K., Rogers N.K. et al. Toy laser macular burns in children. *Eye* 2014;28(2):231-234
15. Al-Sulaiman S.M., Al-Rushood A.A., Al-Masoud J., et al. High-power handheld blue laser-induced maculopathy: the results of the King Khaled Eye Specialist Hospital Collaborative Retina Study Group. *Ophthalmology*. 2014;121(2):566–572.

Patient	Age at Presentation	Laterality	BCVA at Presentation (OD,OS)	Examination Findings	Laser use	Follow-up months
1	9-year-old	Left eye	(6/18, 6/6)	Central scotoma on closing her left eye	Laser Pointer bought from Egypt	12
2	7-year-old	Right eye	(6/9, 6/5)	Hyperpigmentary changes in right eye	Laser toy bought from Spain	11
3	10-year-old	Left eye	(6/6, 6/5)	Micropsia and small vitreous floaters in left eye	Laser toy use	7
4	12-year-old	Both eyes	(6/9, 6/9)	Bilateral multiple macular atrophic lesions	Laser pointer	9
5	11-year-old	Both eyes	(6/12, 6/9)	Retinal pigment epithelium (RPE) disturbance in right macula	Laser toy use	6
6	12-year-old	Left eye	(6/60, 6/6)	Scarring and bleeding in macula of left eye	Laser toy use	12
7	13-year-old	Both eyes	(6/36, 6/9)	Macular burns seen in both eyes with RPE changes	Laser toy use	12
8	6-year-old	Right eye	(6/9, 6/6)	RPE atrophy in right macula	Laser toy use	12
9	10-year-old	Left eye	(6/5, 6/7.5)	Fine drusen in right macula and hypopigmented changes in left macula	Laser toy use	12

Table 1: Summary of the 9 patients

BCVA: Best Corrected Visual Acuity