

Blastic plasmacytoid dendritic cell neoplasm transformed from essential thrombocythemia with leukemic picture and no skin involvement – A case study

Muhammad Mansoor Baig, MBBS, FCPS, FRCPath, Locum Consultant Haematologist, University Hospitals of Morecambe Bay NHS Trust

ABSTRACT

Blastic plasmacytoid dendritic cell neoplasm (BPDCN) is an extremely rare and fatal condition, which usually affects elderly males. It presents in the skin with frequent involvement of the bone-marrow, peripheral blood and lymph nodes. It has a dismal prognosis, with most patients dying within one year. The diagnosis is frequently challenging, with a characteristic immunophenotype. The best modality of treatment remains to be defined. Generally, patients require acute leukaemia-like induction chemotherapy regimen. Here we present a local case who transformed from essential thrombocythemia into BPDCN over a 20-year period with sudden leukemic picture, and interestingly without any typical skin lesions.

INTRODUCTION

Blastic plasmacytoid dendritic cell neoplasm (BPDCN) is an aggressive haematological tumour affecting elderly males in the majority of cases. It usually presents with cutaneous lesions with or without bone marrow involvement. Isolated skin lesions are frequently the first symptom leading patients to seek medical advice, and without therapy they rapidly disseminate. Patients typically present with asymptomatic, solitary or multiple skin lesions that can be variable in size (from a few millimetres to 10cm), shape and colour, and can appear as nodules, plaques or bruise-like infiltrates. The skin lesions can be associated with erythema, hyperpigmentation, purpura or ulceration.¹ In suspected cases immediate biopsy and discussion with haematology is advised to avoid diagnostic delay.

Lymphadenopathy, splenomegaly and cytopenia due to bone marrow involvement can be present at diagnosis or may occur at disease progression. When bone marrow is involved, the most common findings in the peripheral blood are thrombocytopenia (78%), anaemia (65%) and neutropenia (34%). Hyperleukocytosis is infrequent, but the presence of blasts in the blood is more commonly observed. Circulating malignant cells can be detected by morphological review or flow cytometric analysis of the peripheral blood. Morphologically, they appear as monomorphic, poorly differentiated, intermediate-sized blasts.^{1,6-10}

Approximately 10–20% of patients have a previous history of myeloid malignancies.⁴ Diagnosis requires biopsy of the suspected site with specialist investigations including immunophenotype, immunohistochemistry. Being an aggressive neoplasm of predominantly elderly males^{2,3,6} outcome is usually dismal with the majority of patients dying early in disease and being unfit for intensive treatment options.^{1,2,6}

CASE STUDY

A gentleman in his mid-70's was diagnosed with JAK 2 + essential thrombocythemia over 20 years ago when investigated for thrombocytosis. He was initially started on aspirin and cytoreduction with hydroxycarbamide but switched to anagrelide due to hydroxycarbamide related infected leg

ulcers. He tolerated anagrelide quite well with good control of his essential thrombocythemia over many years. His other co-morbid conditions were – hypothyroidism, vitamin B12 deficiency, macular degeneration in both eyes, chronic kidney disease and benign prostatic hypertrophy.

In 2018, he developed mild monocytosis, leucoerythroblastic features on blood film along with a drop in haemoglobin which led to bone marrow assessment. In June 2018, bone marrow showed essential thrombocythemia is transformed into myelofibrosis with no excess in blasts. He was detected positive for molecular mutations including JAK-2, TET-2, ASXL-1, /SF3B1 and was 46 XY (normal) on cytogenetics.

In November 2020 he suddenly developed leucocytosis with total WBC's over 100, circulating blasts in peripheral blood film along with anaemia. He was started on cytoreduction with hydroxycarbamide along with transfusion support, which worked for him in terms of counts control. An urgent repeat bone marrow biopsy was diagnostic of BPDCN with large number of blasts. At this time, he also acquired clonal abnormalities with abnormal karyotype including additional (9q) del (9p) and abnormalities in 18p/22q from previous normal karyotype back in 2018. This supports clonal evolution over a period of years. Next generation sequencing was carried out which showed a rise in burden of molecular mutations; ASXL-1 went from 17% to 38% and TET-2 from 26/28% to 44/46%.

He was made aware of bone marrow results and the dismal outcome of the disease. Subsequently he was discussed in the regional multi-disciplinary meeting and assessed at the tertiary centre. Due to his age and frailty, he was deemed to be unfit for any chemotherapy and local palliative supportive care was suggested by the tertiary centre. He did receive supportive care from the Macmillan cancer team in the community and sadly died within few months of diagnosis.

MANAGEMENT AND OUTCOME

Diagnosis is made as per WHO criteria:³

Biopsy of affected organ with required specialist Investigations.

Characteristic morphology of plasmacytoid dendritic cells including large pseudopodia microvacuoles eccentric nuclei heterogeneous cytoplasm, as shown below (figure 1) in bone marrow aspirate images.

Flow cytometry – Neoplastic cells express CD4, CD43 (also termed SPN), CD45RA and CD56 (also termed NCAM1), as well as the plasmacytoid dendritic cell-associated antigens CD123 (also termed IL3RA), BDCA-2 (also termed CD303, CLEC4E) TCL1 and CTLA1 (also termed GZMB). Lack of expression of markers for B cells, T cells, myeloid or monocytic cells, and NK cells. Flow plots are identified in diagram below (figure 2).

Cytogenetics – no specific single chromosomal aberrations, often 5q, 6q, 9, 12p, 13q, and 15q.¹⁻⁶

Blastic plasmacytoid dendritic cell neoplasm transformed from essential thrombocythemia with leukemic picture and no skin involvement – A case study Muhammad Mansoor Baig

Bone Marrow Aspirate images of Plasmacytoid dendritic cells showing:

Large pseudopodia, Vacuolation

Eccentric nuclei, Heterogenous cytoplasm

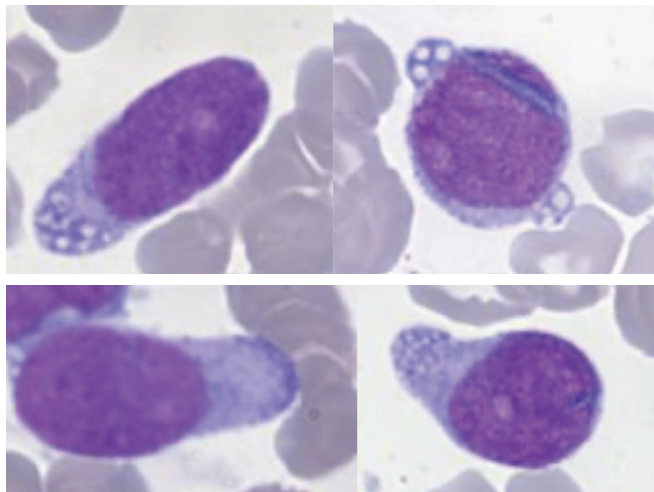


Figure 1: Images courtesy of Dr Alesia Khan, Leeds HMDS Teaching Hospitals NHS Trust.

Bone Marrow Aspirate flow cytometry

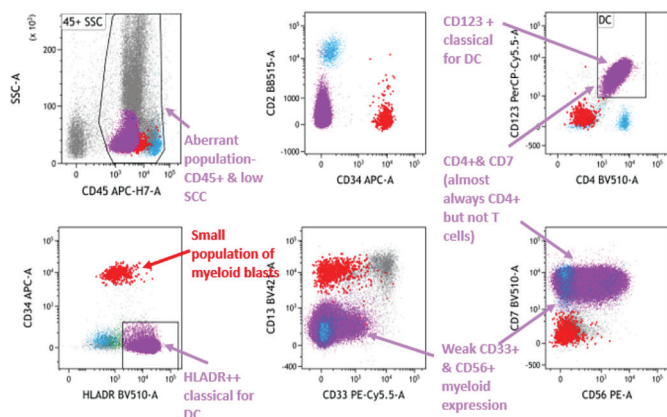


Figure 2

TREATMENT

There are no NICE approved treatments specifically authorised for BPDCN and no standard of care treatment has been established for patients with treatment-naïve (newly diagnosed) or previously-treated (relapsed/refractory) disease in the United Kingdom. Worldwide, it is usually treated with acute lymphoblastic leukaemia/acute myeloid leukaemia like protocols followed by allogeneic bone marrow transplant if the patient is fit enough.^{1, 2, 6} Other options are palliative chemotherapy and best supportive care. A few novel/targeting agents are in the pipe line including Anti-CD 123 (Elzonris) but are not yet approved. Being an aggressive neoplasm of predominantly elderly males, outcome is usually dismal with the majority of patients dying early in disease.^{1, 6}

DISCUSSION

Blastic plasmacytoid dendritic cell neoplasm, being a rare and highly aggressive tumour, would require high clinical suspicion in suspected cases and would require immediate diagnostic workup. Usually, haematology malignancy diagnostic services (HMDS) services are required for specialised investigations.

In the majority of cases, patients present with single/multiple skin lesions to GPs, and/or dermatologists; requiring an urgent biopsy for correct diagnosis. Immediate discussion with the haematology team is advised in suspected cases.

Approximately 10–20% of patients have a previous history of myeloid malignancies; it would require keeping an eye on such patients in haematology follow ups.

It can present with sudden leukemic picture with no skin manifestations at all, like in our case, and would require picking it up on blood film and arranging an immediate clinical review and required diagnostic work up from the haematology end. Management should be planned under the appropriate multi-disciplinary meeting.

ACKNOWLEDGMENTS

Alesia Khan, Consultant Haematologist at Leeds HMDS Teaching Hospitals NHS Trust and Daniel Payne, Leeds HMDS Teaching Hospitals NHS Trust.

Correspondence to:
Muhammad.baig@mbht.nhs.uk

REFERENCES

- Pagano L, Valentini CG, Grammatico S, Pulsoni A. Blastic plasmacytoid dendritic cell neoplasm: diagnostic criteria and therapeutical approaches. *Br J Haematol.* 2016;174(2):188-202. Available from: <https://doi.org/10.1111/bjh.14146>
- Sapienza MR, Pileri A, Derenzini E, et al. Blastic plasmacytoid dendritic cell neoplasm: state of the art and prospects. *Cancers.* 2019;11(5):595. Available from: <https://doi.org/10.3390/cancers11050595>
- Swerdlow S, Campo E, Harris NL, et al. Eds. WHO classification of tumours of haematopoietic and lymphoid tissues. Lyon: International Agency for Research on Cancer; 2017.
- Facchetti F. Plasmacytoid dendritic cell neoplasms. In: Orazi A, Weiss LM, Foucar KA, Knowles DM, eds. *Knowles neoplastic hematopathology.* 3rd ed. Philadelphia PA: Lippincott Williams & Wilkins, 2013.
- Feuillard J, Jacob MC, Valensi F, et al. Clinical and biologic features of CD4+ CD56+ malignancies. *Blood.* 2002;99(5):1556-63. Available from: <https://doi.org/10.1182/blood.v99.5.1556>
- Garnache-Ottou F, Vidal C, Biichlé S, et al. How should we diagnose and treat blastic plasmacytoid dendritic cell neoplasm patients? *Blood Adv.* 2019;3(24):4238-51. Available from: <https://doi.org/10.1182/bloodadvances.2019000647>
- Julia F, Petrella T, Beylot-Barry M, et al. Blastic plasmacytoid dendritic cell neoplasm: clinical features in 90 patients. *Br J Dermatol.* 2013;169(3):579-86. Available from: <https://doi.org/10.1111/bjd.12412>
- Pagano L, Valentini CG, Pulsoni A, et al. Blastic plasmacytoid dendritic cell neoplasm with leukemic presentation: an Italian multicenter study. *Haematologica.* 2013;98(2):239. Available from: <https://doi.org/10.3324/haematol.2012.072645>
- Rauh MJ, Rahman F, Good D, et al. Blastic plasmacytoid dendritic cell neoplasm with leukemic presentation, lacking cutaneous involvement: case series and literature review. *Leuk Res.* 2012;36(1):81-6. Available from: <https://doi.org/10.1016/j.leukres.2011.07.033>
- Wang H, Cao J, Hong X. Blastic plasmacytoid dendritic cell neoplasm without cutaneous lesion at presentation: case report and literature review. *Acta haematol.* 2012;127(2):124-7. Available from: <https://doi.org/10.1159/000334703>