

Immuno-oncology therapy and COVID-19: What are the potential benefits and risks of undergoing immune checkpoint inhibitor-based therapy for advanced non-small cell lung cancer during a COVID-19 pandemic?

Daniel Myers, 4th Year Medical Student, Lancaster University, MBChB

ABSTRACT

Introduction: The COVID-19 pandemic raises several challenges around the treatment of non-small cell lung cancer (NSCLC) using immune checkpoint inhibitor (ICI) based therapy. ICI-therapy, also known as immuno-oncology (IO) therapy, is an upcoming approach to cancer management for several indications, and works by blocking key immune checkpoints, which enables the immune system to destroy tumour cells. Challenges include the potential risk of more severe/frequent immune-related adverse events (irAEs) in COVID-19 patients.

Aim: Explore the risks and benefits of IO-therapy for NSCLC during a COVID-19 pandemic and review current guidelines.

Case presentation: Patient X is a 70-year-old man with NSCLC who has resumed ICI-therapy after sustaining COVID-19 lung changes following his recent infection.

Method: Medical histories were taken from three ICI-patients with NSCLC. In addition, a literature review was undertaken, looking at databases including PubMed, Medline, and Scopus. Key words such as 'covid-19', 'immunotherapy' and 'NSCLC' were used to identify relevant literature and the literature reviewed ranged from 2015 to present day.

Results: Several studies identified poor clinical outcomes associated with IO-therapy use in lung cancer patients throughout this pandemic. However, a large body of literature suggests IO-therapy does not influence the survival of patients with COVID-19 nor the likelihood of severe complications. Thus, complete discontinuation of IO may not be necessary, though many studies did suggest that greater COVID-19 surveillance of IO patients be implemented.

Significance: Cases such as Patient X, who have COVID-19 lung changes and resume IO, are rarely seen in the literature; therefore, there is minimal guidance for similar situations. This study highlights vital areas for future research including the implications of a COVID-19 vaccine.

Conclusion: It is possible for NSCLC patients to undergo IO-therapy during the COVID-19 pandemic. However, the interaction between SARS-CoV-2 and IO-therapy is poorly understood, resultantly it is advised that a case-by-case approach is utilised and patients are involved in the uncertainty of decision-making.

INTRODUCTION

The impact of the COVID-19 pandemic

The SARS-CoV-2 virus, which was first reported by officials in Wuhan, China in December 2019, has since spread rapidly around the globe and represents a major threat to global health.¹ As at 29th November 2020 the virus has infected over 61.8 million individuals worldwide and has resulted in over 1.5

million deaths.² The pandemic has had extensive impacts on healthcare across the United Kingdom (UK), notably affecting cancer screening, diagnostics, and treatment.³ In particular, COVID-19 has presented several challenges surrounding the use of ICI-therapy for NSCLC.

Immune checkpoint inhibitors

Despite the use of platinum-based chemotherapeutic agents, the outlook for patients with advanced, non-resectable NSCLC has remained poor with response rates ranging between 20% to 40%.⁴ However, advances in immuno-oncology have led to the development of ICIs, which use monoclonal antibodies (MoAbs) to block immune checkpoints, thus enabling the immune system to attack tumour cells. Costimulation mediated by B7 and CD28 is required for T cell activation, though inhibitory signals from CTLA-4 (cytotoxic T-lymphocyte-associated protein 4) and PD-1 (Programmed death 1) checkpoints act to suppress T-cell response. Typically, only Tregs (T regulator cells) and MDSCs (Myeloid derived suppressor cells) express PD-L1 (Programmed death ligand 1) proteins on their cell surface membrane, which bind to complementary PD-1 receptors on cytotoxic T cells, inducing a state of exhaustion.⁵ However, cancer cells also express PD-L1, which enables them to 'exhaust' CD8+ T cells and prevent tumour lysis. Therefore, by using MoAbs targeting CTLA-4, PD-1, and PD-L1 it is possible to re-establish anti-tumour responses.^{5,6}

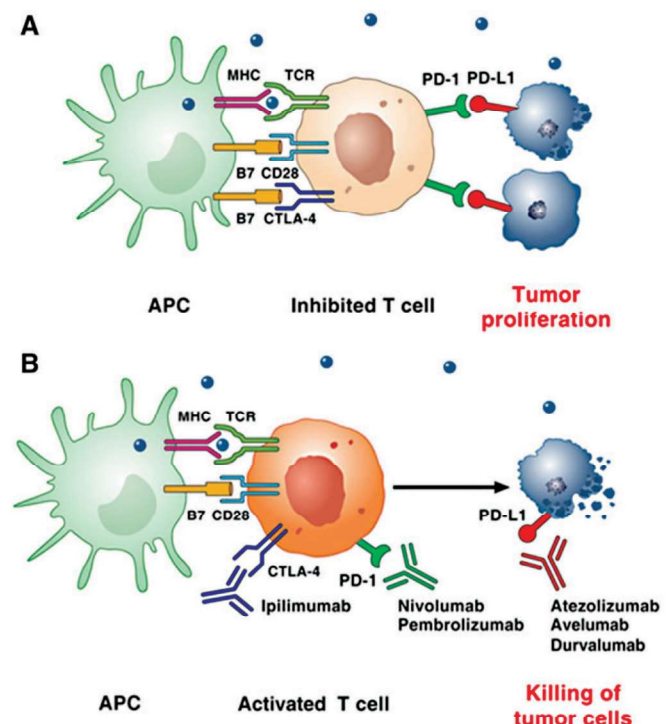


Figure 1: (A) Tumour cells escaping immune attack by promoting the activation of checkpoint proteins (B) Mechanism of checkpoint inhibition via anti-CTLA4, -PD-1, and -PD-L1 MoAbs (6).

ICI treatment has been found to produce greater overall responses in patients with advanced NSCLC in comparison to conventional chemotherapy, alongside prolonging overall survival (OS). As a result, ICI-therapy is being utilised as first line treatment for an increasing number of indications.⁷

Risks of undergoing ICI therapy

Despite the apparent efficacy of ICI-therapy, many cancers are resistant to IO and it carries the risk of patients developing potentially life-threatening irAEs or sustaining infusion reactions.⁵ Tissues most commonly affected by ICI toxicities include the skin, colon, endocrine organs, liver and lungs.⁸

Given the current climate, irAEs associated with the lungs are of particular concern, especially in patients with advanced NSCLC. Checkpoint inhibitor pneumonitis (CIP) occurs in approximately 3-5% of patients receiving ICIs, and up to 20% in those with NSCLC.⁹⁻¹¹ Although this may be higher for those who have had COVID-19 and they may experience more severe outcomes.

COVID-19 lung changes

The SARS-CoV-2 virus is known to cause complications such as pneumonia, acute respiratory distress syndrome (ARDS), fibrotic lung disease, bronchiectasis, and pulmonary vascular disease.^{12,13} In addition, histological damage includes diffuse alveolar damage (DAD), interstitial infiltration of lymphocytes, pneumocytes hyperplasia, exudation, and hyaline membrane formation.^{14,15} As for radiological presentation, typical early CT features of COVID-19 lung damage comprise of ground glass opacities (GGO) located in peripheral and subpleural

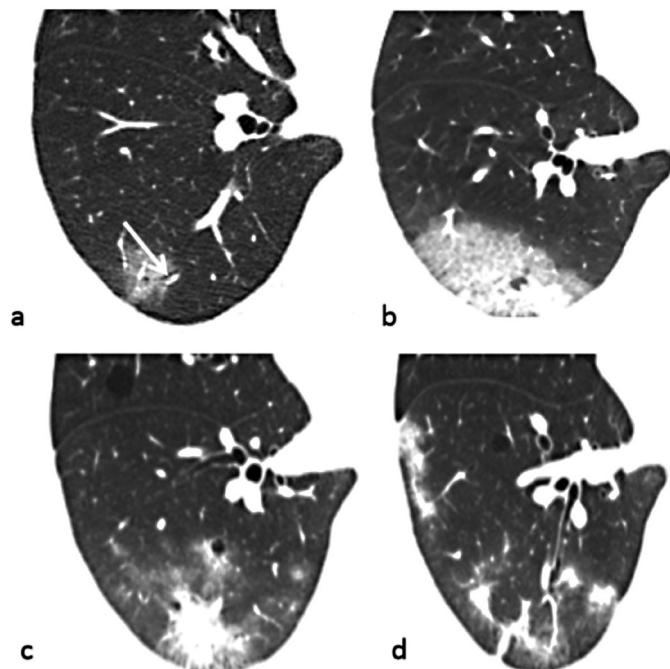


Figure 2: (a) GGO lesion in peripheral and subpleural region, posterior basal segment of right lower lobe. Intralobular interstitium and air bronchogram visible. (b) Progression of GGOs. (c and d) Gradual resolution of lesion (16).

regions with pulmonary artery dilation. Despite the resolution of these radiological features in many patients, studies have found that reticulation can persist for at least 4 weeks after COVID-19 onset.¹⁶

Aims of the study

Herein, using a case-based approach, this paper endeavours to investigate the potential risks and benefits of ICI-therapy in patients with advanced NSCLC during the COVID-19 pandemic, and review available guidelines for patient management.

CASE PRESENTATION

Patient X is a 70-year-old man who was diagnosed with synchronous primary adenocarcinoma lung tumours in November 2019. He was initially treated with carboplatin, pemetrexed and pembrolizumab; however, in March 2020 his treatment was paused due to the COVID-19 outbreak. In June, he resumed treatment with pembrolizumab, although in July it was deferred due to suspected pembrolizumab-related nephritis (for which he was given prednisolone). In August, there was a rise in his creatine levels, so prednisolone was resumed and pembrolizumab was further deferred. At this time, a CT scan showed ongoing response on the left side and stable disease on the right. Patient X's treatment was again deferred by two weeks after testing COVID-19 positive on September 21st. In October, the patient reported increased shortness of breath when attending clinic for the first time after his COVID-19 infection. A chest x-ray (CXR) was therefore undertaken that identified non-specific changes in keeping with COVID lung changes, infection and cancer progression, and a chest CT scan confirmed COVID lung changes. Therefore, pembrolizumab remained on hold in accordance to relevant NICE guidelines.¹⁷ However, during his most recent consultation on 24th October it was apparent his symptoms of COVID-19 had subsided and by this point, he had had a repeat COVID test that was negative, full pulmonary function tests (PFT) and a repeat CXR showing partial resolution of recent changes. Thus, it was decided that pembrolizumab would resume on 27th October.

METHODOLOGY

Throughout this study, three patients with advanced NSCLC were interviewed in order to explore their experience of ICI-therapy. Full informed consent was obtained, nothing was recorded/quoted and only questions typical of a medical history were asked. After speaking to all three patients and carrying out preliminary research it was decided that Patient X would be used as the main stem of this research paper, as his situation raised several key challenges in relation to NSCLC management during the COVID-19 pandemic.

An extensive literature review was then carried out to put issues raised by Patient X's case in context with existing medical knowledge and to explore further the risks and benefits of IO-therapy during the COVID-19 pandemic (refer to appendix 2 for reporting methodology template).

FINDINGS

What are the challenges of undergoing IO during the COVID-19 pandemic?

A retrospective cohort study across three hospitals in Wuhan, China investigated the risk factors associated with severe complications in COVID-19 patients. The study included 28 cancer patients with COVID-19, 25% of which had lung cancer, and one patient was receiving chemoimmunotherapy. Data on patient demographics and baseline clinical characteristics (e.g. prior treatment) were obtained from medical records and univariate and multivariate analyses were utilised to evaluate risk factors for severe complications. It was found that patients whereby systemic anti-cancer therapy (SACT) had been administered within 14 days before the COVID-19 diagnosis had a higher risk of developing severe events. Overall, the study suggests poor clinical outcomes for lung cancer patients on SACT. It was recommended that robust COVID-19 screening in patients receiving SACT take place, and that any treatments causing immunosuppression either be suspended or given in minimal doses.¹⁸

In addition, poor clinical outcomes were also suggested by a case report of a 53-year-old man who had been receiving nivolumab for metastatic NSCLC, and developed hyperacute fatal pneumonitis after contracting COVID-19. The man had a history of oesophageal squamous cell carcinoma, which had been treated with surgery and adjuvant chemotherapy 20 years prior, and underwent a right superior bilobectomy for adenocarcinoma. However, in March 2018 he was diagnosed with bilateral lung metastases, for which he maintained prolonged stabilisation on second line nivolumab with no irAEs. Unfortunately, on March 7 2020 he experienced sudden onset of fever and dyspnoea that led to him being hospitalised. A chest CT scan revealed diffuse bilateral GGO indicative of viral infection and a rapid RT-PCR test confirmed it was COVID-19. His vitals rapidly worsened despite oxygen supplementation and he died 12 hours after onset of symptoms. Like the Wuhan study, this case report also advocated more intensive surveillance for individuals receiving IO throughout the COVID-19 pandemic, with the view to diagnose asymptomatic COVID infection earlier.¹⁹

COVID-19 and IO-therapy synergy

The patient's clinical presentation in the aforementioned report was particularly atypical as the pneumonitis developed after 21 months of nivolumab, while ICI-induced pneumonitis often develops within the first 3 to 6 months.²⁰ In addition, the hyperacute clinical course is also unusual for a COVID-19 infection as the average duration from the onset of COVID-19 symptoms to ICU admission is approximately 10 days.²¹ Therefore, it was suggested by the author that the novel clinical situation of this patient could be explained as a negative synergistic effect of COVID-19 and IO-therapy. This hypothesis appears convincing, as it is apparent there is a significant overlap in ICI mechanisms and COVID-19 pathogenesis, as COVID-19 pneumonia and CIP appear to be the result of abnormal inflammation and dysfunctional lymphocyte activity.²² Perhaps revoking CD8+ T cell functionality promotes excessive proinflammatory cytokine release, which is a major cause of ARDS in COVID-19 patients.²³ However, there are very few cases similar to this documented, which could be explained

by the novelty of the COVID-19 pandemic, or simply that the patient happened to develop a particular severe COVID-19 infection. If this synergising hypothesis were true, it would be expected that more patients on IO-therapy who have contracted COVID-19 would face similar situations, and subsequently more cases would be reported. Undoubtedly, the interaction between IO-therapy and COVID-19 is still poorly understood and so further research is warranted to explore the frequency of severe complications/irAEs in patients on IO who have contracted COVID-19.

Why should IO therapy continue throughout the COVID-19 pandemic?

Conversely, a significant amount of the literature appeared to support the use of ICI-based therapy for NSCLC during the COVID-19 pandemic. This includes the multicentre observational 'Thoracic Cancer International COVID-19 Collaboration (TERAVOLT) Registry' study, which collected data from the first 200 patients with thoracic cancer (mostly NSCLC) entered into the register, 144 of which received SACT. The study collected data on baseline demographics (e.g. smoking habits), patients' baseline characteristics (e.g. comorbidities), cancer diagnosis, and patients' COVID-19 illness. It was found that the type of SACT (including chemotherapy, tyrosine kinase inhibitors [TKIs], and immunotherapy) did not affect the survival of patients with COVID-19, thus suggesting that discontinuing such therapies out of concern of potential risks may not be necessary.²⁴

This is further confirmed in a case study report that discusses two patients, a 74-year-old man and a 51-year-old woman, who have previously received IO for cutaneous melanoma and contracted SARS-CoV-2. Both were suspected to be initially asymptomatic for COVID-19 but then developed symptoms including fever (> 38°C), dyspnoea, cough, nausea, asthenia, and headaches. COVID-19 was confirmed in both cases via an RT-PCR COVID-19 test, and the 74-year-old man was hospitalised (due to symptom severity), whilst the 51-year-old woman quarantined at home. COVID-19 symptoms eventually subsided in both patients, and after two subsequent swab tests showed a negative COVID-19 test result, both resumed ICI treatment.²⁵

DISCUSSION

Issues with immunosuppression and IO-therapy

Although the Wuhan study¹⁸ concluded that immunosuppressive treatment should either be suspended or given in reduced doses, it can be assumed that IO-therapy for most patients does not result in immunosuppression, as it works to revoke functional CD8+ T cell exhaustion.¹¹ Thus, ICI-therapy may be permissible despite poor outcomes reported, which are likely due to methodological flaws such as retrospective nature, lack of randomisation, small sample size and exclusion of confounders in the multivariate analysis (e.g. cancer stage).

However, it is important to note that neutropenia, whilst uncommon in IO-monotherapy, does occur in $\geq 1/1,000$ to $< 1/100$ cases, and is more common in combination therapy.²⁶ The use of corticosteroids and immunosuppressant agents (to treat irAEs), alongside neutropenia, can compromise the patient's immunity, thus increasing their risk of severe COVID-19 complications. Therefore, the conclusions drawn

from the Wuhan study¹⁸ may still be applicable to a minority of patients, thus ICIs must be used with caution. It is also recommended that ICI-monotherapy be administered in NSCLC patients as first line management where applicable to reduce the risk of chemo-induced haematological side effects and immunosuppression.^{27,28} In light of the methodological limitations of this study, prospective, longitudinal research that analyses a broader range of patient characteristics is warranted.

Prevalence of cases in the literature

Similar limitations to the Wuhan study¹⁸ were also identified in the methodology of the TERAVOLT study,²⁴ such as a small sample size of patients receiving SACT. This is most likely due to the low prevalence of COVID-19 patients with advanced NSCLC who have received ICI-therapy. However, this is likely to change, due to increased COVID-19 testing amongst patients on treatment and increased use of IO during the ongoing pandemic. IO is increasingly utilised during this pandemic as the duration of the pandemic is such that NSCLC patients cannot wait until it is over before resuming treatment, and there is a growing confidence that risks from COVID-19 to patients on IO are not as great as initially anticipated from earlier studies, such as the Wuhan study.¹⁸ One notable strength of the TERAVOLT study is the prospective nature of utilising a longitudinal database (unlike the Wuhan study), which with time will allow for a more compressive analysis of COVID-19 patients in receipt of SACT, as more cases are reported.²⁴

Applicability of case studies to Patient X

Moreover, the case-study report of the two-melanoma patients demonstrated that it is possible to recover from a COVID-19 infection whilst on IO without catastrophic consequences.²⁵ However, there may be limitations in the applicability of this study to NSCLC patients such as Patient X, as COVID-19 infection outcomes are often worse for lung cancer patients compared to others, irrespective of SACT.²⁹ In addition, as previously mentioned NSCLC patients on IO face a higher risk of developing pneumonitis, which could further potentiate COVID-19 complications.

Although an overwhelming body of research suggests IO should continue throughout the pandemic it is important not to overlook the case of the patient who died from hyperacute pneumonitis, as the situation demonstrates the potential life-threatening complications that could arise from IO therapy during the pandemic.¹⁹ If the 'synergy' hypothesis were true, it could have important implications for patients such as Patient X who have resumed IO and have COVID-19 lung changes, in terms of increasing the risk of irAEs/severe outcomes.

Issue with generalisability

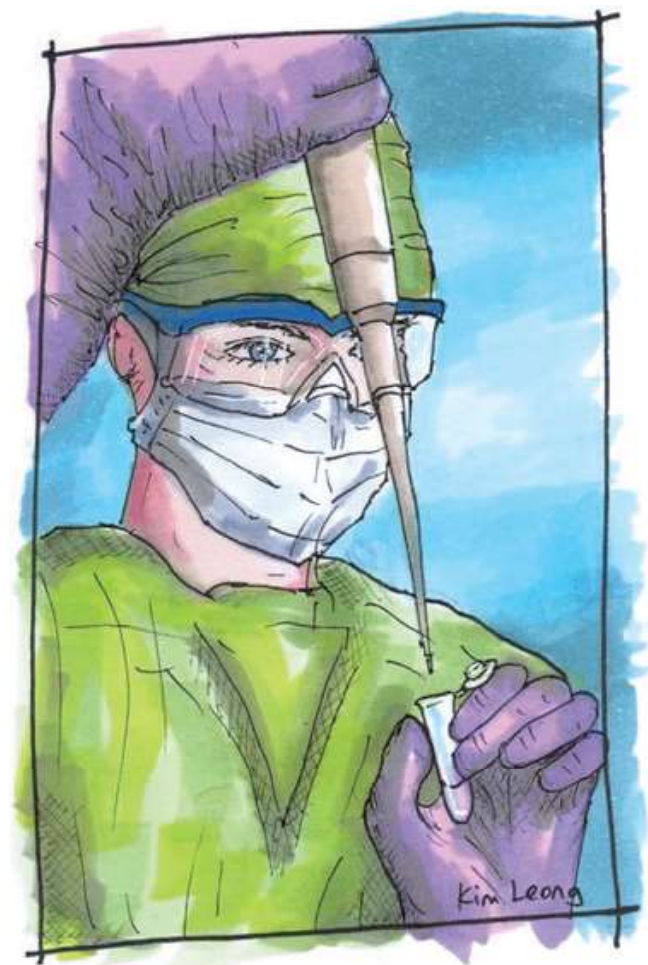Undoubtedly, a further limitation to this research is that the outcomes of Patient X and patients mentioned in the reported studies cannot be generalised to all NSCLC patients in receipt of IO. It is therefore recommended that oncologists take a case-by-case approach to assess individual risks and benefits. For instance, the ECOG performance scale quantifies the functional status of cancer patients and can aid treatment decisions.³⁰ Supplementary to this, oncologists can utilise risk assessment tools to support management decisions in cancer

patients with COVID-19 symptoms, for example 'COVID-19 Risk in Oncology Evaluation Tool (CORONET)'.³¹

What do local guidelines suggest?

Moreover, local guidelines for 'University Hospitals Morecambe Bay NHS Trust' advise that individualised decision-making is needed prior to (re)commencing SACT, which is supported in the literature reviewed in this study, and that SACT suspension is favoured in patients diagnosed with COVID-19 unless needed for urgent cancer control.³² However, these guidelines appear limited, as they do not address patients who sustain COVID-19 lung changes. Patient X recently restarted pembrolizumab, as there was no evidence to suggest that he would not respond well to this treatment, as it had previously been successful. He was also informed that there might be an increased chance of severe outcomes in the event of developing CIP now he has COVID lung changes. However, as suggested by this paper, it is not yet possible to quantify the risks associated with resuming IO having sustained COVID lung changes with any accuracy.

Despite an extensive literature search, no patients with COVID-19 lung changes resuming IO were identified. Thus, ensuring this case is added to the published literature once the longer term consequences of resuming IO are known would be of benefit. Patient X will receive three monthly CT scans alongside a repeat lung function test in three months from writing this paper, in light of his COVID lung changes.



COVID by Kim Leong

Immuno-oncology therapy and COVID-19: What are the potential benefits and risks of undergoing immune checkpoint inhibitor-based therapy for advanced non-small cell lung cancer during a COVID-19 pandemic?

Daniel Myers

The decision to resume IO after a COVID-19 infection is a challenge oncologists currently face and requires further research investigating the frequency/severity of irAEs in IO-patients with COVID lung changes to answer, with confidence, if and when it would be safe for Patient X to resume treatment.

What are the implications of a COVID-19 vaccine for NSCLC patients on IO?

It is likely the guidance will have to be updated for the inclusion of a COVID-19 vaccine once the safety and efficacy is determined for IO-patients. There was initially some uncertainty regarding the risks of the influenza vaccine, particularly the frequency/severity of irAEs and risk of generalised infections. However, this vaccine is now recommended in IO-patients in light of its apparent efficacy.³³⁻³⁵ Furthermore, the efficacy of the COVID-19 vaccine is still unknown, especially since it is not yet clear if the vaccine prevents subclinical infection and onward transmission. If there is subclinical infection, it may be relevant to the potential 'synergy' between COVID-19 and IO-pneumonitis, which could lead to severe outcomes in vaccinated patients. Of course, future research is needed to assess whether there is an increase in frequency/severity of irAEs in vaccinated patients in receipt of ICIs.

CONCLUSION

In summary, the case of Patient X and the literature reviewed suggest that it is possible for NSCLC patients to undergo ICI-therapy during the COVID-19 pandemic. However, it is recommended that oncologists take a case-by-case approach when assessing risks against benefits of ICI-therapy and involve the patient in the uncertainty around decision-making. As well as this, limiting healthcare contact where possible and using ICI-monotherapy preferentially over chemoimmunotherapy is also recommended. Further research into the indications of severe COVID-19 complications and irAEs for patients on IO-therapy is warranted to support oncologists throughout this pandemic.

Correspondence to:
d.r.myers@lancaster.ac.uk

REFERENCES

1. World Health Organisation. Coronavirus disease 2019 (COVID-19) Situation Report – 94 2020 [cited 2020 Dec 06]. Available from: <https://www.who.int/docs/default-source/coronaviruse/situation-reports/20200423-sitrep-94-covid-19.pdf#:~:text=The%20first%20human%20cases%20of,%2C%20in%20December%202019> (accessed 05 April 2023)
2. World Health Organisation. COVID-19 Weekly Epidemiological Update 01 December 2020 [updated 29 November 2020; cited 2020 Dec 6]. Available from: <https://www.who.int/publications/m/item/weekly-epidemiological-update---1-december-2020> (accessed 05 April 2023)
3. Cancer Research UK. Health Professional COVID-19 and Cancer Hub. Available from: https://www.cancerresearchuk.org/health-professional/diagnosis/hp-covid-19-and-cancer-hub#HP_COVID-191 (accessed 05 April 2023)
4. Assi HI, Kamphorst AO, Moukalled NM, Ramalingam SS. Immune checkpoint inhibitors in advanced non-small cell lung cancer. *Cancer*. 2018;124(2):248-61. Available from: <https://doi.org/10.1002/cncr.31105>
5. Wecker L. Brody's Human Pharmacology. 6 ed. Philadelphia, PA: Elsevier; 2019.
6. Varricchi G, Galdierro MR, Tocchetti C.G. Cardiac toxicity of immune checkpoint inhibitors: cardio-oncology meets immunology. *Circulation*. 2017;136(21):1989-1992. Available from: <https://doi.org/10.1161/CIRCULATIONAHA.117.029626>
7. Zhou G-W, Xiong Y, Chen S, Xia F, Li Q, Hu J. Anti-PD-1/PD-L1 antibody therapy for pretreated advanced nonsmall-cell lung cancer: A meta-analysis of randomized clinical trials. *Medicine*. 2016;95(35):e4611.
8. Haanen JBAG, Carbone F, Robert C, et al. Management of toxicities from immunotherapy: ESMO Clinical Practice Guidelines for diagnosis, treatment and follow-up. *Ann Oncol*. 2017; 28(suppl_4):iv119-iv142. Available from: <https://doi.org/10.1093/annonc/mdx225>
9. Suresh K, Naidoo J, Lin CT, Danoff S. Immune checkpoint immunotherapy for non-small cell lung cancer: benefits and pulmonary toxicities. *Chest*. 2018;154(6):1416-23. Available from: <https://doi.org/10.1016/j.chest.2018.08.1048>
10. Naidoo J, Page DB, Li BT, et al. Toxicities of the anti-PD-1 and anti-PD-L1 immune checkpoint antibodies. *Ann Oncol*. 2015;26(12):2375-91. Available from: <https://doi.org/10.1093/annonc/mdv383>
11. Gambichler T, Reuther J, Scheel CH, Becker JC. On the use of immune checkpoint inhibitors in patients with viral infections including COVID-19. *J Immunother Cancer*. 2020;8(2). Available from: <https://doi.org/10.1136/jitc-2020-001145>
12. Fraser E. Long term respiratory complications of covid-19. *BMJ*. 2020;370:m3001. Available from: <https://doi.org/10.1136/bmj.m3001>
13. John Hopkins Medicine. What Coronavirus does to the lungs 2020 [Available from: <https://www.hopkinsmedicine.org/health/conditions-and-diseases/coronavirus/what-coronavirus-does-to-the-lungs> (accessed 05 April 2023)]
14. Tabary M, Khanmohammadi S, Araghi F, Dadkhahfar S, Tavangar SM. Pathologic features of COVID-19: A concise review. *Pathol Res Pract*. 2020;216(9):153097. Available from: <https://doi.org/10.1016/j.prp.2020.153097>
15. Jain A. COVID-19 and lung pathology. *Indian J Pathol Microbiol*. 2020;63(2):171-2. Available from: https://doi.org/10.4103/IJPM.IJPM_280_20
16. Hu Q, Guan H, Sun Z, et al. Early CT features and temporal lung changes in COVID-19 pneumonia in Wuhan, China. *Eur J Radiol*. 2020;128:109017. Available from: <https://doi.org/10.1016/j.ejrad.2020.109017>
17. NICE. COVID-19 rapid guideline: delivery of systemic anticancer treatments 2020 [updated Nov 9, 2020; cited 2020 Dec 15]. Available from: <https://www.nice.org.uk/guidance/ng161/chapter/3-Patients-known-or-suspected-to-have-COVID19> (accessed 05 April 2023)
18. Zhang L, Zhu F, Xie L, et al. Clinical characteristics of COVID-19-infected cancer patients: a retrospective case study in three hospitals within Wuhan, China. *Ann Oncol*. 2020;31(7):894-901. Available from: <https://doi.org/10.1016/j.annonc.2020.03.296>
19. Di Noia V, D'Aveni A, Squadroni M, Beretta GD, Ceresoli GL. Immune checkpoint inhibitors in SARS-CoV-2 infected cancer patients: the spark that ignites the fire? *Lung Cancer*. 2020;145:208-10. Available from: <https://doi.org/10.1016/j.lungcan.2020.05.006>
20. Remon J, Mezquita L, Corral J, Vilariño N, Reguart N. Immune-related adverse events with immune checkpoint inhibitors in thoracic malignancies: focusing on non-small cell lung cancer patients. *J Thorac Dis*. 2018;10(Suppl 13):S1516-s1533. Available from: <https://doi.org/10.21037/jtd.2017.12.52>
21. Yang X, Yu Y, Xu J, et al. Clinical course and outcomes of critically ill patients with SARS-CoV-2 pneumonia in Wuhan, China: a single-centered, retrospective, observational study. *Lancet Respir Med*. 2020;8(5):475-81. Available from: [https://doi.org/10.1016/S2213-2600\(20\)30079-5](https://doi.org/10.1016/S2213-2600(20)30079-5)
22. Russano M, Citarella F, Napolitano A, et al. COVID-19 pneumonia and immune-related pneumonitis: critical issues on differential diagnosis, potential interactions, and management. *Expert Opin Biol Ther*. 2020;20(9):959-64. Available from: <https://doi.org/10.1080/14712598.2020.1789097>
23. Ye Q, Wang B, Mao J. The pathogenesis and treatment of the 'Cytokine Storm' in COVID-19. *J Infect*. 2020;80(6):607-13. Available from: <https://doi.org/10.1016/j.jinf.2020.03.037>

(a full list available on request)