

Fast-Bleeped: A to E Series – Traumatic Cardiac Arrest

Guilherme Movio, Intercalating Medical Student,^{1,3} Poppy Bowler, Intercalating Medical Student,² Joseph Wilson, Foundation Year 1 Doctor,³ Aarohi Shah, Emergency Medicine Speciality Trainee Year 5³

¹ Urgent and Emergency Care BSc, Kings College London/Plymouth University, ² Urgent and Emergency Care BSc, Northern General Hospital/Plymouth University, ³ King College Hospital, Emergency Department, London

A medical educational series comprising practical instructional pieces on how to approach undifferentiated clinical problems in the acute setting

CASE PRESENTATION

You are the Foundation Year 2 (FY2) surgical doctor covering a major trauma centre (MTC) hospital on a night shift. One of your responsibilities is attending trauma calls and assisting the team. Just after midnight you receive a bleep requesting you to urgently attend the Emergency Department (ED) resuscitation room for an incoming trauma patient. On your arrival, you read the pre-alert sheet, which tells you that the patient is a 20-year-old male with a penetrating knife wound to the chest. Observations were not given over the pre-alert. The ED consultant identifies herself as the trauma team leader (TTL) and she asks you to conduct the primary survey and allocates

roles to the other team members present. You are reminded to communicate all your findings out loud to the team. Other colleagues supporting you are the ED registrar, intensive care unit (ICU) registrar, surgical registrar, and ED nursing team.

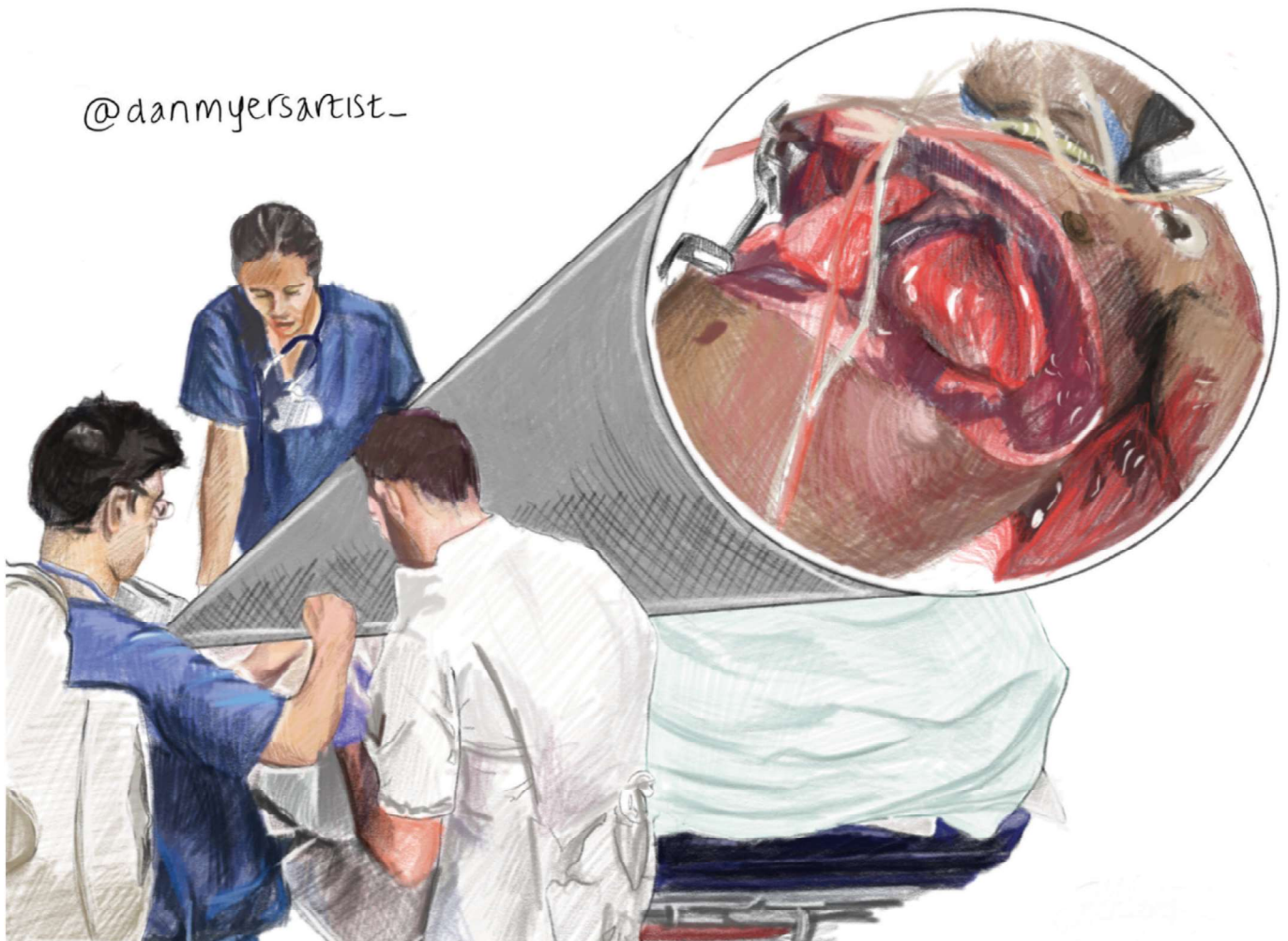
On arrival, the patient appears pale and has a fluctuating consciousness level. He is rapidly moved on to the hospital trolley, and his clothing is cut using tough-cut scissors.

HOW WOULD YOU APPROACH THIS CLINICAL SCENARIO?

You begin your assessment as per Advanced Trauma Life Support (ATLS) guidelines.¹

(C)ervical spine: Given the mechanism of injury, the patient has been brought to ED without a spinal board and his C-spine has not been immobilised by the pre-hospital team. The nurses have already attached the patient to a continuous cardiac monitor and two large bore cannulas are being inserted.

@danmyersartist_



Fast-Bleeped: A to E Series – Traumatic Cardiac Arrest

Guilherme Movio, Poppy Bowler, Joseph Wilson, Aarohi Shah

(A)irway: The patient can speak and identifies himself as Mr G. You deem the airway is patent and there are no signs of impending airway obstruction such as stridor, stertor or any surgical emphysema. The ICU registrar agrees with your observations and applies high-flow oxygen to the patient's face.

(B)reathing: Mr G is obviously tachypnoeic and has saturations of 90% on high-flow oxygen. On inspection, there is a 4cm incision within the left pectoral region of his chest. It is oozing blood, so you ask a member of the trauma team to apply firm pressure. There is no left sided chest expansion and breath sounds are absent there. The TTL promptly interrupts and instructs the ED registrar to insert a surgical chest drain, due to suspicion of a haemothorax. You are asked to continue your assessment as the procedure is being undertaken.

(C)irculation: The blood pressure (BP) returns at 80/40mmHg, and the heart rate (HR) is 135 beats per minute (BPM). The peripheral capillary refill time (CRT) is also prolonged at five seconds. These signs immediately concern you, as you conclude the patient is likely in hypovolemic shock due to haemorrhage.² The TTL had recognised these signs on arrival and asked for O-negative blood to be taken from the ED fridge and prepared for administration. You make space for the nurses to attach the blood onto the cannula. By this point, the chest drain has been inserted and is draining blood. There is a rapid discussion between all team members with agreement to activate a "code red". This will put an emergency operating theatre on 'stand-by' so that it will be ready to accept a patient for emergency damage control surgery (DCS) as well as notify the blood bank that further blood product support is likely to be required. The ED registrar undertakes a fast-scan, and reports that there is free fluid within the left pleural space but also within the pericardium. There is no free intra-abdominal fluid on ultrasound. This prompts the TTL to ask one of the nurses to fast-bleep the cardiothoracic surgeon on-call to come to the resuscitation room.

(D)isability: A rapid Glasgow Coma Score (GCS) is calculated at 13 (E3V4M5). His pupils are size three and reactive bilaterally. The patient can move all four limbs.

(E)xposure: You remember the importance of not being distracted by obvious injuries. With the support of the nurses, you quickly expose the patient and look for any other hidden injuries. The ED consultant reminds you to also inspect the perineal area, as this is a common location for hidden stab wounds.³ You find no other wounds. The glucose on the venous blood gas (VBG) taken during canulation is 4.5mmol/L.

As you begin your reassessment, the monitors begin to alarm, and you notice that Mr G has become bradycardic. The BP cuff keeps re-cycling and is unable to get a reading. He then becomes unresponsive, and the ICU registrar reports to the team that he is unable to feel for central pulses. A lot happens now all at once. A member of the team goes to start chest compressions but is asked to stand down by the TTL who instead asks for the resuscitative thoracotomy (RT) trolley to be opened. The cardiothoracic surgeon arrives as the ICU registrar intubates the patient. The TTL states that given this is a witnessed cardiac arrest in the context of penetrating cardiac injury they have decided to proceed with a RT.

What is the algorithm for traumatic cardiac arrest?

Traumatic cardiac arrest (TCA) is rare and is known to have a poor prognosis.⁴ However, due to new advanced trauma techniques and a greater understanding of the pathophysiology, survivors are becoming more frequent.⁴ The main reversible causes are hypoxia, tension pneumothorax, cardiac tamponade, and hypovolaemia. An algorithm from the Royal College of Emergency Medicine (RCEM) is shown in Figure 1.⁵

What is the evidence for resuscitative thoracotomy (RT)?

TCA associated with penetrative chest trauma is an indication for consideration of RT, as per RCEM guidelines (Figure 1).^{5,6} RT is a procedure aimed to "damage-control" prior to formal surgical intervention.⁷ Survival rates for penetrative trauma are significantly higher than blunt trauma.⁸⁻¹⁰ RCEM report that without a "chain of survival" (with surgical support), a RT would most likely be futile and should not be performed.¹¹ RT is a time-critical procedure and should be performed within ten minutes from cardiac arrest and ideally when the patient has a "low-flow state in trauma".¹² Patients who have TCA and undergo RTs in the ED are more likely to survive than those in the pre-hospital setting, likely due to fast access to surgical

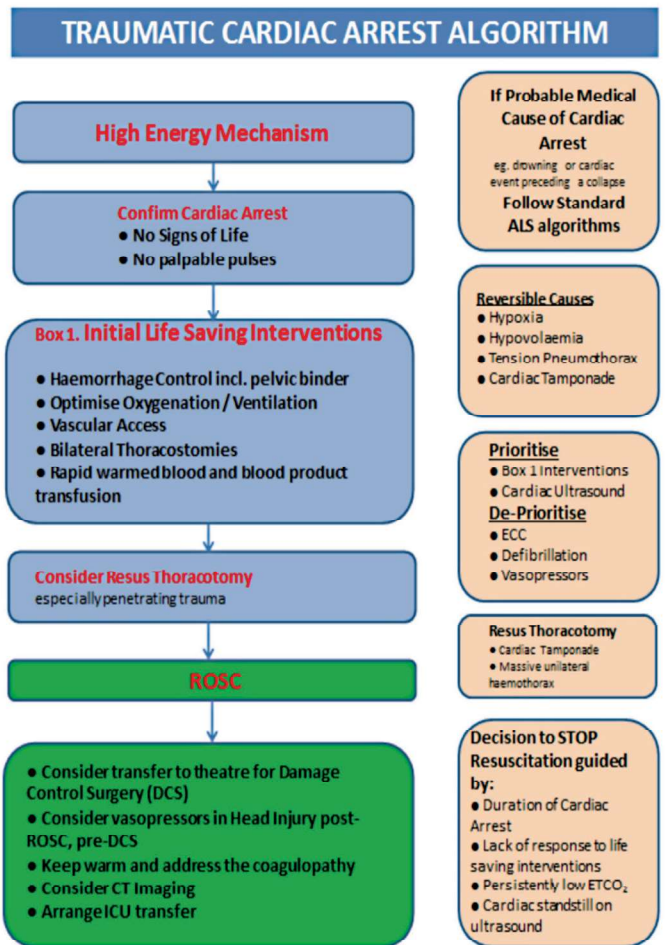


Figure 1: Traumatic cardiac arrest management algorithm.⁵

services.⁴ An American study evaluating 4,620 RTs for TCA conducted in ED showed an overall survival rate of 7.4%; when stratified, penetrating chest trauma caused by a knife had a survival of 16.8%.¹³

The UK evidence base for RT is scarce. It is made up of several observational studies and smaller-scale case series with high heterogeneity, meaning any conclusions made have restricted value in guiding clinical practice.¹⁴ The Trauma Audit Research Network (TARN) gathers data on patients who receive RTs, however, issues in their data collection have been identified. For example, patients receiving RTs who die in the pre-hospital settings are not included, and the use of non-clinical coders confers risk of miscoding of two different procedures: thoracotomy and thoracostomy.¹⁵ There is an ongoing prospective UK study “Trauma Emergency Thoracotomy for Resuscitation in Shock” (TETRIS) aiming to evaluate current RT practice which will be used to inform future guidelines.¹⁵

What are the life-threatening complications, and consequent life-saving procedures in chest trauma?

The trauma primary survey is rooted in quickly, yet comprehensively, assessing the patient to identify life threatening physiological and anatomical derangements, and prompt resuscitative interventions to correct or stabilise those derangements (where possible).¹ The compromise (shock), or complete loss of cardiac output is an immediate life-threatening consequence of trauma. One cause of shock in the context of trauma is hypovolaemia due to haemorrhage. The mainstay of management is balanced resuscitation with rapid infusion of blood products but in severe cases, this can be temporarily managed with aortic occlusion, of which there are minimally invasive and open approaches.^{4, 16, 17}

Resuscitative endovascular balloon occlusion of the aorta (REBOA) is a temporising measure to control active haemorrhage.¹⁷ A catheter is inserted into the common femoral artery and a balloon inflated within the descending aorta, thus preventing flow and further exsanguination. Common to all aortic occlusion approaches is the need to occlude the aorta as distally as possible to avoid unnecessary adverse perfusion of organs and tissues. REBOA aortic compression is divided into three zones (zone 1, 2, 3). A Japanese study comparing REBOA with cross clamping found REBOA to be associated with reduced mortality¹⁸ however, a new UK trial comparing REBOA to standard care reported REBOA increased mortality at 90 days and at all interim time points.¹⁹ REBOA is a contentious issue in trauma care.

If taking an open approach to access the intra-thoracic aorta, a RT is required.⁵ A thoracotomy is a surgical procedure to visualise and access the key structures within the thorax, such as the heart, lungs, aorta. In trauma, this is typically a bilateral anterior thoracotomy with transverse sternotomy, or clamshell procedure: bilateral incisions are made in the fifth intercostal space between the mid-axillary line and the sternum, with scissors then used to transect the sternum.⁵ This allows the anterior superior chest wall to be lifted, reminiscent of a clam opening. Myocardial disruption in penetrating chest trauma can also lead to catastrophic haemorrhage and should be acted on during the primary survey if there is profound haemodynamic instability, or loss of cardiac output. This is managed with direct suturing of the heart. This defect can

initially be plugged with either a catheter or a finger, followed by more definitive repair.⁵

Aside from hypovolaemia, cardiac tamponade is another common cause of shock or cardiac arrest in trauma. This is caused by fluid within the pericardium, which consequently prevents cardiac pre-load. Tamponade can be managed by accessing the thorax with a thoracotomy, and then pericardiectomy (opening of the pericardial sac).⁵ This relieves the extrinsic pressure that prevents the heart from filling.

Tension pneumothorax, caused by massive haemothorax or a pleural lesion is another potential life-threatening insult that can present in trauma patients. Clinically this is characterised by hypoxia, unilateral reduced chest expansion with hyperresonance to percussion and no breath sounds on auscultation. Tracheal deviation to the contralateral side is also sometimes seen.²⁰ In an emergency, there are multiple ways of managing a tension pneumothorax, each more definitive than the next. Initially, a needle decompression can be done by inserting a wide bore needle (14-gauge) perpendicularly into the thorax in the fifth intercostal space either in the mid-clavicular line, or just anterior to the mid-axillary line.²⁰ If achievable, a finger thoracostomy may also be the initial approach: a small incision is made with a scalpel in the fifth intercostal space from just anterior to the mid-axillary line towards the sternum. This is followed by blunt dissection with forceps, before using a gloved finger to breach the chest wall; you can touch the lung with your finger to confirm you are in the pleural cavity. It is important to stay as close as possible to the superior aspect of the rib below to avoid damage to the intercostal bundle that runs along the inferior aspect of the rib above. Following thoracostomy, a chest tube can be inserted into the existing thoracostomy site; this should aim to sit in the apex of the lung and position should be confirmed with chest x-ray.²¹

What is the trauma network, in England?

Major trauma remains the most common cause of death in the population under 40 years of age. In 2007, the NCEPOD report “Trauma, who cares?” identified failings within the organisation of trauma care in the United Kingdom (UK).²² Since then, changes have been imposed and the care of these patients has become centralised at trauma units, and at MTCs. In England there are 27 MTCs in total. These comprise of adult only, paediatric only and mixed centres. MTCs are supported by smaller trauma units. MTCs provide consultant-led emergency access to specialists including anaesthetics, orthopaedics, neurosurgical, intensivist, and emergency doctors.²³

Different regions of England operate similar triage tools to allow paramedics and pre-hospital clinicians to decide which patients should be moved to a MTC. The London Major Trauma Triage Decision Tool, shown in Figure 2 is a well-recognised triage tool.²⁴ The only exception is if the patient has an unstable airway where guidelines instruct clinicians to divert to the closest trauma unit to allow for prompt management.

Outcome of case

Once a decision was made to proceed with resuscitative thoracotomy, the cardiothoracic and surgical registrar both performed thoracostomies on each side of the chest. They then extended the incision around the chest and cut through the xiphisternum with tough-cut scissors. The incision was then opened using rib spreaders. As this was being done, blood

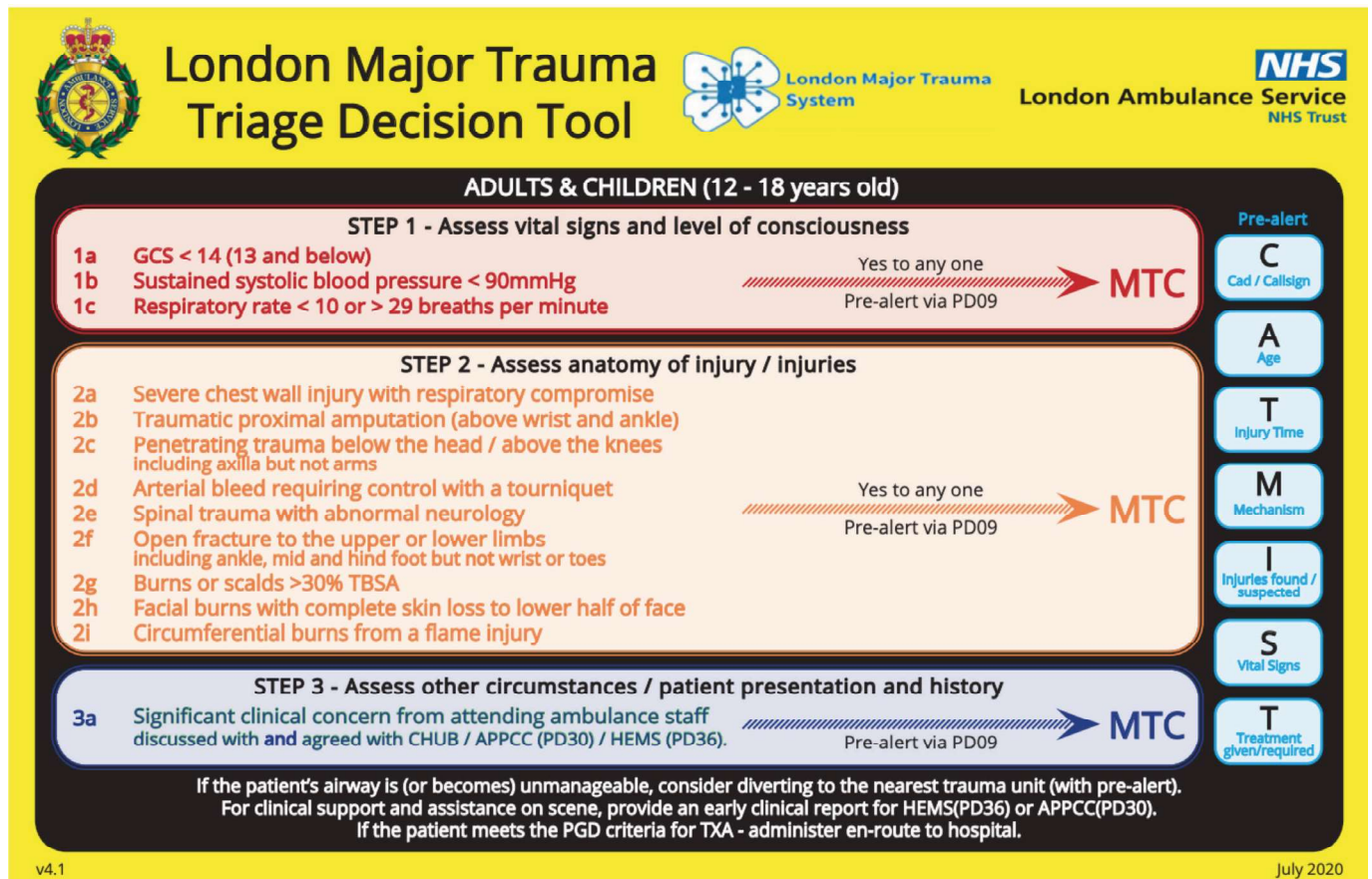


Figure 2: London Major Trauma triage decision tool.²⁴

was given via a rapid infuser. The surgeon then tented the pericardium with forceps and made a midline longitudinal incision using scissors. This allowed for clots to be removed, evacuating the tamponade. Return of spontaneous circulation was achieved, but an incision through the right ventricle was noted. Finger occlusion was done initially, then replaced with an inflated urinary foley catheter and then a stitch attempted.⁶ The heart required some manual compression, but then slowly improved.

The decision was made to stop interventions in ED and rapidly move Mr G to theatre. There, an in-depth exploration of the heart was done, and further sutures were placed. The clamshell incision was also closed. Mr G was moved to the ICU, and neuroprotective measures were started in view of his cardiac arrest. Three days later, sedation was stopped, and he slowly regained consciousness with good neurological outcome. He was extubated and moved to the ward and eventually was discharged home with ongoing physiotherapy, psychological and youth-worker support.

ACKNOWLEDGEMENT

I would like to acknowledge Daniel Myers for producing the excellent illustration for this piece.

DISCLAIMER

The article is provided as a study and revision aid and is not intended to be a substitute for formal medical education. It is important to always seek senior support in clinical practice and never work beyond your capabilities. The Morecambe

Bay Medical Journal will assume no liability to any person or entity with respect to any loss or damage related directly or indirectly to any information provided through the written article (including any action or inaction taken or not taken because of such information).

Correspondence to:
 g.movio@lancaster.ac.uk

REFERENCES

- Galvagno SM, Nahmias JT, Young DA. Update 2019: Management and applications for adults and special populations. *Anesthesiol Clin.* 2019;37(1):13-32. Available from: <https://doi.org/10.1016/j.anclin.2018.09.009>
- Wilson RF, Wilson JA, Gibson D, Sibbald WJ. Shock in the emergency department. *JACEP.* 1976;5(9):678-90. Available from: [https://doi.org/10.1016/s0361-1124\(76\)80100-1](https://doi.org/10.1016/s0361-1124(76)80100-1)
- Clark S, Westley S, Coupland A, Hamady M, Davies AH. Buttock wounds: beware what lies beneath. *BMJ Case Rep.* 2017 Oct 24;2017:bcr2017220425. Available from: <https://doi.org/10.1136/bcr-2017-220425>
- Smith JE, Rickard A, Wise D. Traumatic cardiac arrest. *J R Soc Med.* 2015;108(1):11-6. Available from: <https://doi.org/10.1177/0141076814560837>
- Royal College of Emergency Medicine. Best Practice Guideline: Traumatic cardiac arrest. 2019. Available from: <https://rcem.ac.uk/new-traumatic-cardiac-arrest-in-adults-september-2019/> (accessed on 15 September 2023)
- Wise D, Davies G, Coats T, Lockey D, Hyde J, Good A. Emergency thoracotomy: "how to do it". *Emerg Med J.* 2005;22(1):22-4. Available from: <https://doi.org/10.1136/emj.2003.012963>
- Khan M, Di Saverio S. What's new in emergencies trauma and shock? Resuscitative thoracotomy in emergency room - selective not obligatory. *J Emerg Trauma Shock.* 2021;14(1):1-2. Available from: https://doi.org/10.4103/JETS.JETS_167_20

8. Seamon MJ, Haut ER, Van Arendonk K, et al. An evidence-based approach to patient selection for emergency department thoracotomy: A practice management guideline from the Eastern Association for the Surgery of Trauma. *J Trauma Acute Care Surg.* 2015;79(1):159-73. Available from: <https://doi.org/10.1097/TA.0000000000000648>
9. Burlaw CC, Moore EE, Moore FA, et al. Western Trauma Association critical decisions in trauma: resuscitative thoracotomy. *J Trauma Acute Care Surg.* 2012;73(6):1359-63. Available from: <https://doi.org/10.1097/TA.0b013e318270d2df>
10. Schulz-Drost S, Mersch D, Gumbel D, et al. Emergency department thoracotomy of severely injured patients: an analysis of the TraumaRegister DGU®. *Eur J Trauma Emerg Surg.* 2020;46(3):473-85. Available from: <https://doi.org/10.1007/s00068-019-01212-3>
11. Royal College of Emergency Medicine. Position statement on resuscitative thoracotomy in trauma units. RCEM; 20 April 2017. Available from: https://rcem.ac.uk/wp-content/uploads/2021/10/Position_Statement_on_Resuscitative_Thoracotomy-in_Trauma_Units_Apr_-2017.pdf. (accessed 16 September 2023).
12. Paulich S, Lockey D. Resuscitative thoracotomy. *BJA Educ.* 2020;20(7):242-8. Available from: <https://doi.org/10.1016/j.bjae.2020.03.005>
13. Rhee PM, Acosta J, Bridgeman A, Wang D, Jordan M, Rich N. Survival after emergency department thoracotomy: review of published data from the past 25 years. *J Am Coll Surg.* 2000;190(3):288-98. Available from: [https://doi.org/10.1016/s1072-7515\(99\)00233-1](https://doi.org/10.1016/s1072-7515(99)00233-1)
14. Nevins EJ, Moori PL, Smith-Williams J, Bird NTE, Taylor JV, Misra N. Should pre-hospital resuscitative thoracotomy be reserved only for penetrating chest trauma? *Eur J Trauma Emerg Surg.* 2018;44(6):811-8. Available from: <https://doi.org/10.1007/s00068-018-0937-4>
15. Tucker H, Ramage L, Greenhalgh R, et al. Trauma emergency thoracotomy for resuscitation in shock—a multi-centre evaluation of current UK practice of pre-hospital and emergency department resuscitative thoracotomy in trauma. *J Surgical Protocols and Research Methodologies.* 2022;2022(4):snac011. Available from: <https://doi.org/10.1093/jspm/snac011>
16. Harris T, Masud S, Lamond A, Abu-Habsa M. Traumatic cardiac arrest: a unique approach. *Eur J Emerg Med.* 2015;22(2):72-8. Available from: <https://doi.org/10.1097/MEJ.0000000000000180>
17. Aoki M, Abe T. Traumatic cardiac arrest: scoping review of utilization of resuscitative endovascular balloon occlusion of the aorta. *Front Med (Lausanne).* 2022;9:888225. Available from: <https://doi.org/10.3389/fmed.2022.888225>
18. Abe T, Uchida M, Nagata I, Saitoh D, Tamiya N. Resuscitative endovascular balloon occlusion of the aorta versus aortic cross clamping among patients with critical trauma: a nationwide cohort study in Japan. *Crit Care.* 2016;20(1):400. Available from: <https://doi.org/10.1186/s13054-016-1577-x>
19. Qasim Z. The UK REBOA trial: has the balloon popped? *St Emelyn's* 2023. Available from: <https://www.stemlynblog.org/jc-the-uk-reboa-trial-has-the-balloon-popped-st-emelyns/> (accessed on 16 September 2023).
20. Sharma A, Jindal P. Principles of diagnosis and management of traumatic pneumothorax. *J Emerg Trauma Shock.* 2008;1(1):34-41. Available from: <https://doi.org/10.4103/0974-2700.41789>
21. Aylwin CJ, Brohi K, Davies GD, Walsh MS. Pre-hospital and in-hospital thoracostomy: indications and complications. *Ann R Coll Surg Engl.* 2008;90(1):54-7. Available from: <https://doi.org/10.1308/003588408X242286>
22. Alleyway R. Trauma: Who cares? 2007. Available from: <https://www.ncepod.org.uk/2007t.html> (accessed on 15 September 2023)
23. Moran CG, Lecky F, Bouamra O, et al. Changing the system - major trauma patients and their outcomes in the NHS (England) 2008-17. *EClinicalMedicine.* 2018;2-3:13-21. Available from: <https://doi.org/10.1016/j.eclim.2018.07.001>
24. Centre for Trauma Sciences. London Ambulance Service major trauma triage tool. 2020. Available from: <https://www.c4ts.qmul.ac.uk/london-trauma-system/clinical-policies-and-documents> (accessed on 15 September 2023)

Richard Sachs, Director of Governance

University Hospitals of Morecambe Bay NHS Foundation Trust

The trial, verdict and conviction of Lucy Letby; the grief of parents and staff; the media coverage; announcement of an inquiry; the call for stronger measures, controls and consequences for NHS leaders when things go wrong – it's all available to read in your paper or website of choice for most of August and September. Some of it even notes that Lucy Letby was a rare dangerous quirk, and that the vast majority of staff turn up to do an amazing job in some really testing circumstances.

We, that is 'UHMB', have considerable historical experience of a weaponised incident reporting system, of investigations that are not impartial or absent of bias, clinical audits that don't benchmark – we have something to share as a warning to the wider NHS. With PSIRF <https://www.england.nhs.uk/patient-safety/incident-response-framework/> on the horizon in a post-Letby NHS, we have to find the right words to ask worst case scenario questions when exploring the reasons why a patient may have come to harm or worse. Many years ago, this was detailed in the National Patient Safety Agency (remember them?) Incident Decision Tree, that was ultimately replaced with 'A just culture guide': https://www.england.nhs.uk/wp-content/uploads/2021/02/NHS_0932_JC_Poster_A3.pdf – here's a poster of it. On the NHS England website – it explains this as:

'This guide supports a conversation between managers about whether a staff member involved in a patient safety incident requires specific individual support or intervention to work safely.'

I don't pretend to think that this is somehow the means by which Lucy Letby should have been found out – that took some brave staff sticking to their guns. My point is this, I want governance systems, processes, practices that engage, excite even and don't alienate, that are collectively owned because they are fair, transparent, uncomplex and receptive to improvement.

As the passenger in the back of the summer holiday car heading home said, 'Are we there yet?...!', no, not yet, sorry, but we will because what we cannot let happen is a decline into a Spanish inquisition/police state model, yes we must ask the worst case scenario question, but we must do that with grace, humility and a recognition that it's for the purpose of the extraordinarily rare needle in a haystack, who will never come to represent the hard working, value driven NHS staff who do incredible things.

With an inquiry into what went wrong at the Countess of Cheshire to follow, we can't afford to wait for either interim or concluding recommendations to remind us of the duty we have to patients and their families to raise a concern when someone's practice is questionable, sub-optimal or, sadly, criminal. When staff have raised concerns in the NHS the reaction has not always been one of 'listening with fascination', it's not easy to raise a concern and it's often not easy to hear it – what lies at the heart of that is the integrity to speak truth and equal integrity to hear it.

Correspondence to:
Richard.Sachs@mbht.nhs.uk