

Histopathology quiz

Dr Phuoc-Tan Diep, Consultant Histopathologist, UHMB

This is a quiz that tests your ability to recognise two things:

- Firstly what organ is the tissue from
- Secondly what is the malignant tumour

There are seven photomicrographs which contain background tissue and malignant tumour. Match the photos with the possibilities

- Options: A1 Prostate, Prostatic adenocarcinoma
A2 Lymph node, Metastatic adenocarcinoma of the breast
A3 Skin, Melanoma
A4 Lymph node, Non-Hodgkin Lymphoma
A5 Skin, Angiosarcoma
A6 Breast, Invasive lobular carcinoma
A7 Colon, Colorectal adenocarcinoma

See page 180 for the answers.

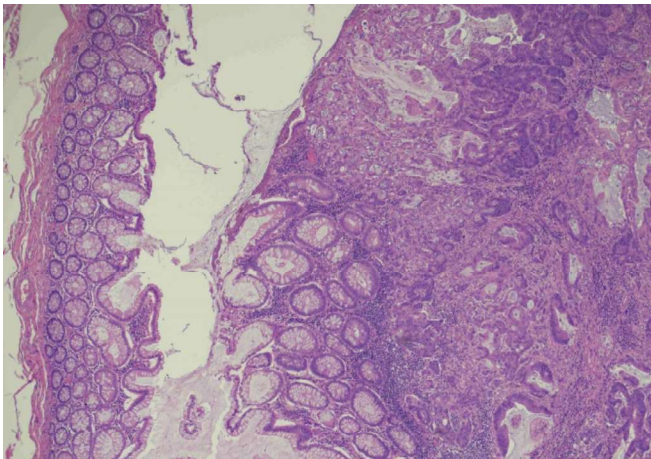
WHAT DO HISTOPATHOLOGISTS DO?

Our main interaction with other doctors is through cancer multi-disciplinary team (MDT) meetings. We are part of the core team and provide the tissue diagnosis which is so often vital for correct management of cancer patients. We also diagnose diseases that are not cancer and we perform post-mortems.

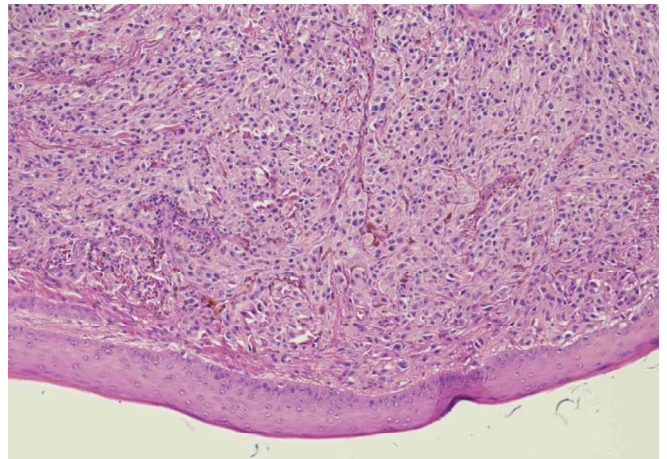
Diagnosing cancers is not a straightforward process. The most important ideas are firstly knowing what is normal and then being able to identify variations from normal. Once a variation from normal has been identified then assessment of multiple parameters are undertaken. Some of the parameters are: amount of disorder, cellularity, cellular atypia, mitoses, necrosis etc.

For those interested in learning more about histopathology, please contact the histopathology lab at the Royal Lancaster Infirmary and we can give you a tour of the lab and what we do.

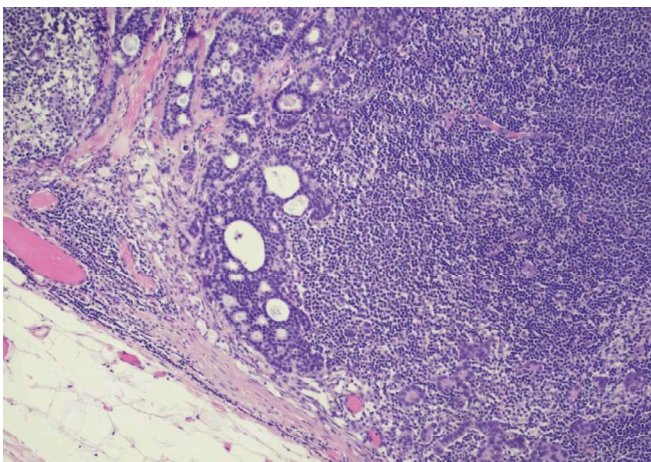
Q1



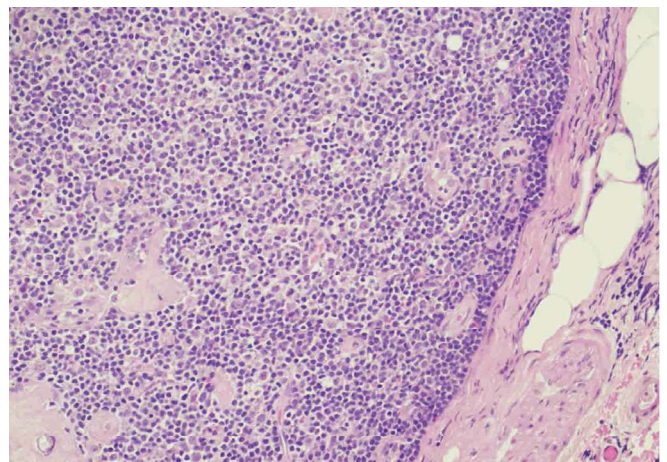
Q2



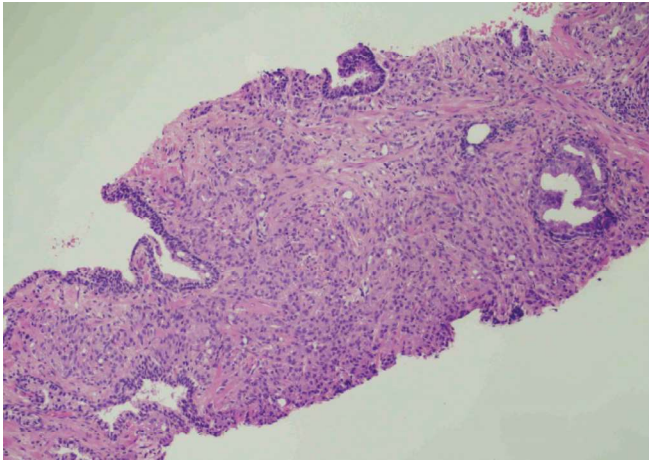
Q3



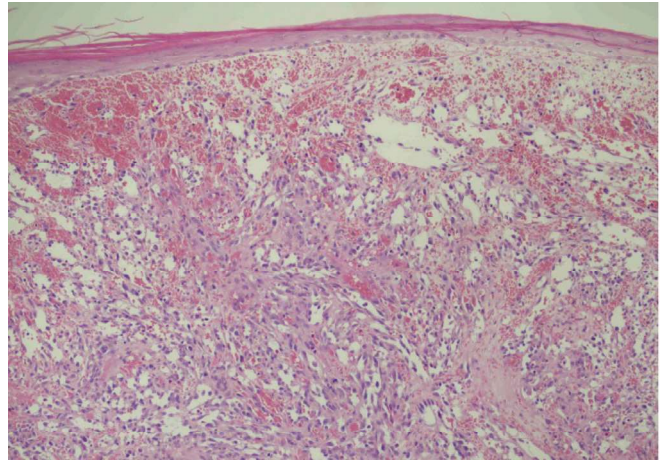
Q4



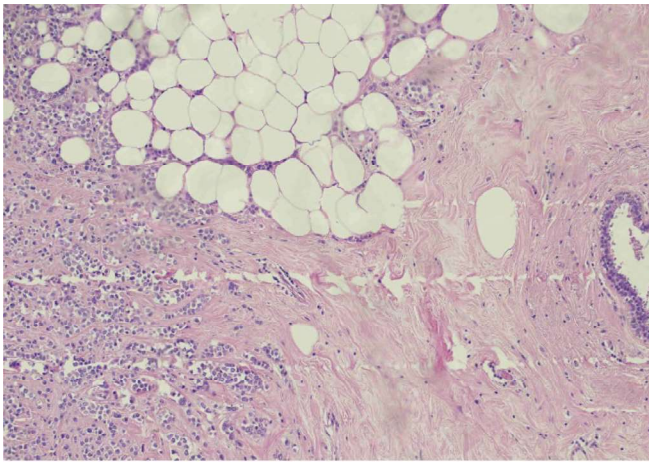
Q5



Q6



Q7



Correspondence to:
 phuoc-tan.diep@mbht.nhs.uk

L&MMBC Badminton Tournaments

