

# Pelvic congestion syndrome: a review of current clinical practice

Wisha Gul

Wisha is a second-year student at Lancaster Medical School

## INTRODUCTION

Chronic pelvic pain (CPP) is a common presenting complaint in gynaecology, accounting for approximately 40% of visits to outpatient clinics. Approximately 15% of the population of women aged 18-50 are thought to have CPP.<sup>(1)</sup>

CPP is constant or intermittent pain in the lower abdominal and/or pelvic region, lasting for six months or longer; that doesn't specifically present with menstruation, sexual intercourse or pregnancy.<sup>(2)</sup>

It is a poorly understood symptom and, therefore, unravelling its specific cause can be challenging. Pelvic congestion syndrome (PCS) is one such cause, which is often overlooked because of the numerous underlying aetiological factors shown below.

### Chronic pelvic pain, differential diagnosis<sup>(3)</sup>

- Bowel pathology
- Cancer/metastases
- Endometriosis
- Fibroids
- Fibromyalgia
- Neurologic pathology
- Ovarian cyst
- Pelvic congestion syndrome
- Pelvic inflammatory disorder
- Porphyria
- Urologic pathology
- Uterine prolapse

PCS is common in multigravids and is described as producing a dull pelvic pain, which is exacerbated by factors that increase intra-abdominal pressure.<sup>(1)</sup> The aetiology is unclear, but it is thought that reflux of blood from inferior vena cava (IVC) and renal veins into the ovarian veins and pelvic venous plexus leads to venous distension forming varicosities causing CPP.<sup>(4)</sup>

The association of CPP with pelvic varicosities was initially described by French doctors in 1857,<sup>(5)</sup> and documented in 1949.<sup>(6)</sup> It wasn't until the 1980s, when this association was demonstrated in 91% of women, that the concept of PCS gained widespread acceptance.<sup>(4)</sup>

### Aim

The aim of this review is to explore whether a causal relationship exists between CPP and PCS. It will also look at the currently employed diagnostic procedures and comment on their specificity and sensitivity. Additionally, the current medical and surgical treatment options will be evaluated and a conclusion drawn to establish the most effective diagnostic and treatment modality.

## CLINICAL FEATURES

PCS is most common in multiparous women; producing a chronic, dull ache. It is similar to that produced by varicosities in the legs.<sup>(7)</sup> There are a range of physiological and psychological associated symptoms, which are summarised below.

### Physiological and psychological associated symptoms of PCS<sup>(7)</sup>

#### Common in multiparous women

**Chronic, dull ache**  
**Unilateral or bilateral**

#### Exacerbations

- post-coital
- pre-menstruation
- increased abdominal pressure due to:
  - standing
  - lifting
  - pregnancy

#### Physiological associated symptoms

- bladder irritability
- abdominal or pelvic tenderness
- dysmenorrhea
- lumbosacral neuropathy
- rectal discomfort
- urinary infrequency
- swollen vulva
- increased vaginal discharge

#### Psychological associated symptoms

- depression
- anxiety

#### Examination findings

- cervical motion tenderness
- point tenderness over ovaries and/or uterus
- varicose veins of vulva, perineum, buttocks or lower extremities

Examination findings comprise of cervical motion tenderness or point tenderness over the ovaries and/or uterus.<sup>(3)</sup> Varicose veins (VVs) of the vulva, perineum, buttocks or lower extremities may also be found. A study in 2000 demonstrated an association between PCS and VVs in the vulva and thighs in 24% and 10% of 41 patients.<sup>(8)</sup> Certainly, it is possible for patients to present to clinic with recurrent VVs as their principle complaint when precise pelvic origin was not identified. These findings, alongside the aforementioned history, is said to be reasonably sensitive and specific for PCS.<sup>(9)</sup>

## AETIOLOGY

The precise aetiology of PCS still remains elusive. An understanding of the anatomical structures in the pelvis will allow us to account for the resulting symptoms.

Figure 1 shows how the ovarian plexus gives rise to the right and left ovarian veins. The left ovarian vein (LOV) drains directly into the left renal vein (LRV) whereas the right ovarian vein (ROV) drains into the IVC just below the right renal vein (RRV).<sup>(17)</sup> The ovarian plexus has connections with the uterine plexus, which in conjunction with the vaginal plexus drains into three uterine veins on each side.<sup>(7)</sup> These in turn, drain into the internal iliac.

Multiple heterogeneous factors lead to ovarian vein reflux into pelvic veins resulting in engorgement and swelling<sup>(11)</sup> that is painful.<sup>(1)</sup> The internal iliac veins, inferior vena cava, but most importantly the ovarian veins, are implicated in the majority of pelvic varices.<sup>(7)</sup> Absence of valves in the LOV and ROV has been noted in 15% and 6% of the cases respectively,<sup>(12)</sup> whereas valvular incompetence and consequent reflux was reflected in 43% (LOV) and 35-41% (ROV) of individuals.<sup>(7,13)</sup>

Congenital absence of valves can be another factor causing primary venous reflux,<sup>(11)</sup> which may explain its presence in nulliparous women diagnosed with PCS.

PCS is found almost exclusively in premenopausal women who've usually had at least one child,<sup>(7)</sup> which suggests multiparity to be a significant contributing factor.<sup>(11)</sup> During pregnancy, ovarian venous flow may increase up to 60 times leading to pelvic venous dilation, which can persist for up to six months, and is compounded by further pregnancies.<sup>(7)</sup> These mechanical changes, alongside the altered hormonal milieu during pregnancy, are all factors contributing to ovarian vein reflux.

Another factor which may be involved, but is uncommon, is venous compression, eg left renal vein compression resulting in nutcracker syndrome, or, more commonly, iliac vein compression (May-Thurner syndrome). These all play an important part in the investigation algorithm of PCS and will be discussed later.

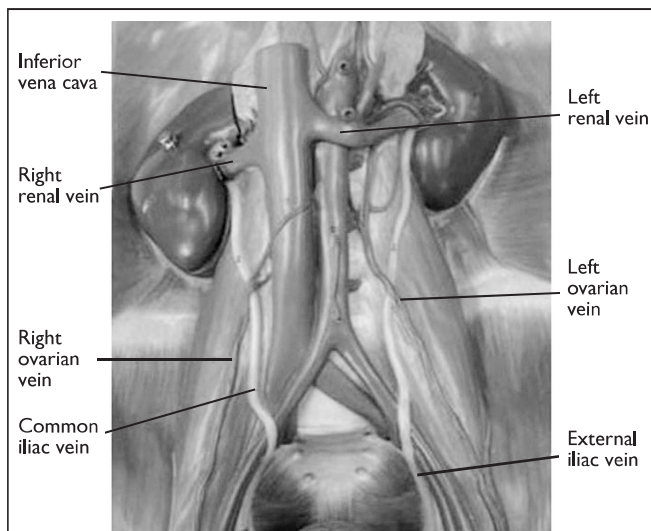


Figure 1 Venous supply in the pelvis, showing LOV draining into the LRV, whereas ROV drains directly into the IVC (We would like to thank Dr Adam Taylor & Dr Quenton Wessels of the Clinical Anatomy Learning Centre at Lancaster Medical School for their assistance in providing this model)

## CAUSAL RELATIONSHIP BETWEEN PCS AND CPP

CPP is a possible consequence of PCS and the suggested aetiology of PCS is ovarian vein reflux, resulting in pelvic varicosities which cause the chronic pain.

However, an interesting debate arises when ovarian vein reflux is found in asymptomatic multiparous women.<sup>(14)</sup> There are a number of studies that demonstrate a significant proportion of the cohort with venous congestion and reflux, but no CPP. This suggests that despite it being a common occurrence, the relationship between the two entities may not be causal. Additionally, women who did complain of CPP did not have any signs of pelvic venous congestion on venography, which confirms the aforementioned challenge in distinguishing between the underlying pathologies which may be causing the CPP.

There's also the possibility of psychological factors playing a role in the genesis of PCS. The intricacy of psychological factors in the condition has been recognised for many years and numerous attempts to describe the psychology are made in the literature. This area was discussed in a seminal paper in 1949.<sup>(6)</sup> Vaginal blood flow of patients during psychiatric interviews was measured. Blood flow was found to be increased when patients presented with anxiety, depression or resentment, and decreased with relaxation. Further studies confirmed this and reported significant associations between social arrangements, childhood psychological disturbance and decreased libido in patients with PCS. This led to the condition being accepted as a psychosomatic illness at the time.

Year of study	Sample	Incidence of dilated veins and/or reflux in asymptomatic women	
2001 <sup>(14)</sup>	Total women	34	63%
	Multi/uni parous	24	10%
	Nulliparous	10	
2004 <sup>(15)</sup>	Total women	151	44%
	Multi/uni parous	110	5%
	Nulliparous	41	
2002 <sup>(16)</sup>	Total women	22	38%

Table 1 Results for asymptomatic women under study (Adapted from <sup>(17)</sup>)

Research in the 1970s onwards was responsible for the resurgence of PCS as being a legitimate cause of CPP. A retrospective case series comprising of 45 women was fundamental in establishing the correlation between CPP and venographically dilated pelvic veins.<sup>(4)</sup> However, this conclusion is open to debate. The control group in the study was composed of eight women, which is too small to include women with venous reflux and no symptoms. Furthermore, a significant number of the sample had a fairly normal ovarian plexus (analogous to the control group). CPP and venous congestion did not necessarily occur synergistically in all women. Further research is, therefore, required to replicate the study to reinforce the correlation beyond doubt.

## DIAGNOSIS

Many women with symptoms of PCS have to undergo a series of extensive investigative procedures before a definitive diagnosis can be made. However, it is anticipated that a greater awareness of the condition amongst physicians will lead to reduction in the need for such prolonged investigations.

There is a wide range of protocols used to investigate patients presenting with PCS-like symptoms; however, a trial to compare the efficiency of the currently used criteria is yet to be published. The first step involved in this investigation is to eliminate other pelvic pathologies and, therefore, by the time the patient presents to an interventional radiologist for additional evaluation, various different forms of imaging have already been utilised. It is postulated that the diagnosis of PCS may often be neglected because the imaging techniques are carried out in the supine position, which can temporarily relieve venous distention.<sup>(3)</sup>

An investigative algorithm to investigate women with PCS-like symptoms has been proposed.<sup>(12)</sup>

The initial step in investigating PCS is the transvaginal echo Doppler (TED), which presents the physician with anatomical structure and haemodynamic information. The abdominal transparietal echo Doppler (ATED) is carried out to identify any venous compression. If the result is positive, further information is gained by carrying out venography.

When pelvic VVs are found without continuous flow, but are dilated and show flow augmentation during TED, venography is still carried out since venous compression is improbable.<sup>(16)</sup> Selective venography then identifies the veins where reflux is present, which is usually the ovarian vein or the iliac vein tributaries.<sup>(16)</sup>

The diagnosis of PCS is based on a combination of features which include: a history that is compatible with the clinical features of PCS, ovarian vein reflux, pelvic venous congestion and no other identifiable pathology to explain the CPP.<sup>(4,9)</sup>

As mentioned before, comparative evidence is not available at present to demonstrate the most effective investigative modality, but it is a general consensus that venography is the 'gold standard' for identifying the pathophysiological features of PCS.<sup>(3,18,19)</sup> Different investigative techniques will be discussed in this review to validate this claim.

## A COMPARISON BETWEEN PELVIC ULTRASOUND, COMPUTED TOMOGRAPHY AND MAGNETIC RESONANCE IMAGING/VENOGRAM

Pelvic ultrasound (US) and/or computed tomography (CT) scan are usually the first imaging techniques employed. They are widely used, particularly because they are non-invasive and US is non-ionising, particularly useful in women of child-bearing age. MRI, although non-invasive, is expensive and is, therefore, not used in primary investigation. Both provide excellent

resolution and a detailed assessment for the pelvic contents and identify varices, as it is possible to alter the patient's position.

MRI and CT scans have many advantages over US, including: greater sensitivity for showing varicose veins, providing a greater more comprehensive view of the pelvic anatomy, and the ability to form reconstructions which is independent of an operator.<sup>(3)</sup> However, US with Doppler is important in providing detailed information on haemodynamic function. Although, these investigative methods are accessible, and can be carried out within 20-30 minutes for most outpatients, they are not as sensitive for identifying PCS as magnetic resonance venography (MRV) or diagnostic venography. Nevertheless, they are important in ruling out other pelvic pathologies, especially malignancies.<sup>(3)</sup>

The criteria for diagnosing varices using sonography are:

- dilated ovarian veins with a diameter  $\geq 4$ mm
- dilated and tortuous veins in the myometrium of the uterus communicating with pelvic varicose veins on both sides
- slow blood flow  $\leq$  than 3cm/s and reversed venous blood flow in the ovarian veins<sup>(3,4)</sup>

The general consensus in the literature viewed is that MRI/MRV is the best first-line imaging modality for the investigation of PCS. It is a non-invasive technique and does not require ionising radiation. It has a greater sensitivity for pelvic varices compared to US or CT, and can be carried out as an outpatient. MRI allows the entire pelvic venous network to be visualised and is also excellent in demonstrating venous pathology.<sup>(3)</sup>

## LAPAROSCOPY

Laparoscopy is another technique employed to find a specific cause of CPP experienced by patients. It has a major advantage in obtaining a direct view to eliminate other specific diseases, eg endometriosis.<sup>(3)</sup> This procedure is also carried out in the supine position and also involves insufflation of CO<sub>2</sub> gas; it can result in venous collapse, thereby giving a false negative diagnosis of PCS.<sup>(3)</sup>

Even if a full laparoscopic view of the pelvis is done before insufflating with CO<sub>2</sub>, the result can still be a false negative in 80-90% of the patients.<sup>(3)</sup>

It is vital to be aware of the patient's position, which is supine, during these investigations. Although advanced pelvic varices would be visible, the less severe cases would be easily masked and may not be seen. Furthermore, other pelvic pathologies may also be revealed such as polycystic ovaries, which are found in 56% of PCS patients.<sup>(1)</sup> These incidental findings may then be attributed to symptoms of PCS. Other features such as increased endometrial thickness may be found, which although found in patients with PCS, may be confused with other conditions such as adenomyosis.<sup>(1)</sup> In conclusion, none of these imaging techniques can be relied on exclusively to make a diagnosis of PCS.

## DIAGNOSTIC VENOGRAPHY

Diagnostic venography has been described as the 'gold standard' tool in the diagnosis of PCS in the literature studied.<sup>(1,3,7,11,19)</sup> It can be performed in two ways: transuterine or percutaneously gaining access through the femoral or internal jugular vein.<sup>(7)</sup>

**Transuterine venography** involves gaining access to the myometrium via a catheter. Contrast is then injected and images taken at 20 and 40 seconds respectively.<sup>(7)</sup> This is less commonly performed compared to selective ovarian venography, because tolerance of the procedure by patients is low and the examination is not as comprehensive.

**Selective ovarian venography** involves gaining access to the ovarian and pelvic veins through the femoral or internal jugular vein using fluoroscopy.<sup>(7)</sup> Contrast is then injected in selected veins. The following is the criterion required to confirm a diagnosis of PCS:<sup>(3)</sup>

- ovarian vein diameter > 6mm
- retrograde ovarian or pelvic venous pathways
- presence of several tortuous collateral pelvic venous pathways
- delayed or stagnant clearance of contrast at the end of the injection

Although the procedure is invasive, requires radiation and the use of contrast, its advantages are far greater, making it a reliable and an efficient diagnostic tool.<sup>(19)</sup> The procedure is performed on a tilt table, which allows the patient's position to be altered and, therefore, it minimises the false negative results greatly, allowing the very subtle cases to be observed. The resulting diagnostic venogram provides detailed and instantaneous information on the haemodynamic function of the veins under study. It further allows measurements of the veins to be taken in order to confirm a diagnosis. Finally, therapeutic procedures such as embolotherapy can be performed immediately.<sup>(6)</sup>

## MANAGEMENT

In the past, women presenting with PCS had limited treatment options. However, improved understanding of the aetiopathogenesis of its symptoms and development of reliable diagnostic methods has helped overcome this problem.

A variety of treatment options, ranging from medical to surgical, have been suggested since Charles Richet (1850-1935) first appreciated a link between CPP and ovarian and pelvic varices.<sup>(3)</sup> Current medical management includes hormonal therapy and analgesics, whereas surgical therapy involves ovarian vein ligation, hysterectomy and oophorectomy, and finally the most preferred – transcatheter embolization.<sup>(3)</sup>

### Medical treatment

Psychotherapy, progestins, danazol, phlebotonics, gonadotropins receptor agonists (GnRH) with hormone replacement therapy (HRT), dihydroergotamine, and non-steroidal anti-inflammatory drugs (NSAIDS) are all examples of treating PCS medically.<sup>(3)</sup>

Progesterones, particularly medroxyprogesterone acetate (MPA), has been supported by various studies to relieve symptoms of PCS in 40% of patients,<sup>(11)</sup> by acting as a vasoconstrictor. However, the benefits are only temporary, reversing after the cessation of treatment.

Etonogestrel (Implanon) has been suggested as an improved substitute to MPA, providing longterm relief. Further research is required since the evidence is only in the form of early pilot studies.

### Surgical treatment

#### *Hysterectomy and oophorectomy*

Surgical treatments described in a 1984 study benefited the patients with PCS in relieving their symptoms.<sup>(20)</sup> This included resection of the LOV. This mode of treatment was also criticised due to problems with the proposed aetiology (incompetent ovarian veins), which was implicated in a high rate of recurrence and residual pain, noticed in approximately 20% and 30% of patients respectively.<sup>(21,22)</sup> Hysterectomies and bilateral oophorectomy is still currently used as a last resort, when other modes of treatments have failed.

#### *Laparoscopic ovarian vein ligation*

In the past, PCS was thought to be a unilateral, left-sided pathology, as only the LOV was adequately studied using selective venography.<sup>(7)</sup> This was reflected in the treatment options which focused on unilateral venous ligation, resulting in limited beneficial outcomes.

It did still gain popularity when performed laparoscopically. However, evidence in terms of surgical experience of ovarian ligation has only been reported by a few case studies. The procedure itself requires anaesthesia and involves insufflation with CO<sub>2</sub> and is carried out in the supine position,<sup>(3)</sup> which undermines its efficiency by causing venous collapse. It can be implicated in increased morbidity, scarring and results in overnight stay of two days.

#### *Trans-catheter embolisation*

Advancements in diagnostic modalities, and heightened knowledge of PCS's aetiology, led to a natural progression from open ligation to intraluminal procedures. Bilateral venous occlusion by embolisation gained popularity as an intervention of choice. It was first proposed in 1993,<sup>(23)</sup> and since has superseded all other treatments of PCS. The procedure is performed by gaining access to bilateral ovarian veins through a femoral approach and a variety of embolic agents, eg sclerosant foam and coils are used to occlude the vessels.<sup>(3)</sup> Iliac veins can also be injected simultaneously or at a subsequent date to reduce the rate of recurrence<sup>(7,13)</sup> Table 2 shows several case series published recently which show significant success rates of the procedure.

These studies show that there was significant improvement in CPP relief following embolisation therapy. The 2006 study involved a sample group of 127 patients and improvement was seen in 83%, with a follow-up term of 45 months.<sup>(24)</sup> Patients also benefited from minimal changes in their hormone levels, menstrual cycle and fertility. In patients where embolotherapy was performed secondary to surgery, still reported improved outcomes. Longterm follow-up reported no recurrence or major complications.<sup>(24)</sup> The 2007 study showed 82% improvement in overall symptoms with a longterm follow-up for 5-6 years of 17 patients.<sup>(25)</sup>

Year of study	No. of patients	Embolisation		Clinical outcome (% patients)	
2000 <sup>(9)</sup>	41	Unilateral ovarian	32	Total relief	58.5
		Bilateral ovarian	9		
2006 <sup>(24)</sup>	127	Bilateral ovarian + internal iliac	106	Improved	83
		Unilateral ovarian + internal iliac	20		
2007 <sup>(25)</sup>	67	Ovarian vein	67	Significant improvement	82
2013 <sup>(21)</sup>	10	Bilateral ovarian + bilateral ileac	10	Significant improvement	50.9
Table 2 50-80% positive clinical outcomes in patients under study (Adapted from <sup>(18)</sup> )					

Embolotherapy is advantageous over other modes of treatment. It can be performed as an outpatient, immediately after venography confirms the findings of PCS. It is minimally invasive, results in better cosmesis, has a technical success rate of 96-100%<sup>(10)</sup> of cases with minimal complication and recurrence rates of less than 22%.<sup>(25)</sup>

Although embolisation is currently the standard treatment for patients with PCS, there are questions over its use as the optimal treatment. The evidence available for its effectiveness is mostly in the form of uncontrolled case series, which may be subjected to a placebo effect. It also does not address the underlying psychological issues in patient with PCS.

No randomised controlled trials (RCTs) have been performed to validate its effectiveness. The only RCT in this field is a 2003 study,<sup>(26)</sup> which compared embolisation with hysterectomy in conjunction with/without oophorectomy in patients with PCS, confirmed with venography, who did not respond to medication for 4-6 months. The results concluded embolisation to be more effective. The study didn't publish its process of randomisation, hence it could have been susceptible to bias.

In conclusion, the current literature supports embolisation to be the standard treatment for treating patients with PCS. Further research is required in the form of RCTs to validate its effectiveness and larger sample sizes need to be studied with longer follow-up periods.

## CONCLUSION

Current literature suggests there is a causal relationship between CPP and PCS, but there are also studies which show that it could be an incidental finding in asymptomatic women. Therefore, further research in the form of systematic reviews is required to assess this causation beyond doubt.

The general consensus is that venography is the diagnostic modality of choice, commonly described as the 'gold standard'. It is advantageous over other diagnostic tools as it can identify subtle cases of PCS, but as it is invasive, should not be used as a primary investigative procedure. Embolisation is the most popular intervention, due to its high success rates, minimal morbidity, better cosmesis and lower recurrence and complication rates. However, further research is required in the form of larger cohorts to discern the best combination of therapies in terms of safety, cost, and longterm efficacy.

## ACKNOWLEDGEMENTS

I am thankful to Mr John Calvey, consultant surgeon at Royal Lancaster Infirmary, for his help and support.

## REFERENCES

- Nicholson T, Basile A. Pelvic congestion syndrome, who should we treat and how? *Tech Vasc Interv Radiol* 2006;9(1):19-23
- Gynaecologists RCoOa. *Chronic Pelvic Pain, Initial Management*. 2nd ed. Royal College of Obstetricians and Gynaecologists. 2012
- Ignacio EA, Dua R, Sarin S, et al. Pelvic congestion syndrome: diagnosis and treatment. *Semin Intervent Radiol* 2008;25(4):361-8
- Beard RW, Highman JH, Pearce S, Reginald PW. Diagnosis of pelvic varicosities in women with chronic pelvic pain. *Lancet* 1984;2(8409):946-9
- MA R. *Traite pratique d'anatomie medico-chirurgicale*. Chamerot et Lauwereyns. 1857
- Taylor HC Jr. Vascular congestion and hyperemia; their effect on structure and function in the female reproductive system. *Am J Obstet Gynecol* 1949;57(2):211-30
- Liddle AD, Davies AH. Pelvic congestion syndrome: chronic pelvic pain caused by ovarian and internal iliac varices. *Phlebology* 2007;22(3):100-4
- Maleux G, Stockx L, Wilms G, Marchal G. Ovarian vein embolization for the treatment of pelvic congestion syndrome: long-term technical and clinical results. *J Vasc Interv Radiol* 2000;11(7):859-64
- Beard RW, Reginald PW, Wadsworth J. Clinical features of women with chronic lower abdominal pain and pelvic congestion. *Br J Obstet Gynaecol* 1988;95(2):153-61
- van der Vleuten CJ, van Kempen JA, Schultze-Kool LJ. Embolization to treat pelvic congestion syndrome and vulval varicose veins. *Int J Gynaecol Obstet* 2012;118(3):227-30
- Rane N, Leyon JJ, Littlehales T, Ganeshan A, Crowe P, Uobero R. Pelvic congestion syndrome. *Curr Probl Diagn Radiol* 2013;42(4):135-40
- Ahlberg NE, Bartley O, Chidekel N. Circumference of the left gonadal vein. An anatomical and statistical study. *Acta Radiol Diagn (Stockh)* 1965;3(6):503-12
- Ahlberg NE, Bartley O, Chidekel N. Right and left gonadal veins. An anatomical and statistical study. *Acta Radiol Diagn (Stockh)* 1966;4(6):593-601
- Rozenblit AM, Ricci ZJ, Tuvia J, Amis ES Jr. Incompetent and dilated ovarian veins: a common CT finding in asymptomatic parous women. *AJR Am J Roentgenol* 2001;176(1):119-22
- Hironomura T, Nishioka T, Nishioka S, Ikeda H, Tomita K. Reflux in the left ovarian vein: analysis of MDCT findings in asymptomatic women. *AJR Am J Roentgenol* 2004;183(5):1411-5
- Nascimento AB, Mitchell DG, Holland G. Ovarian veins: magnetic resonance imaging findings in an asymptomatic population. *J Magn Reson Imaging* 2002;15(5):551-6
- Ball E, Khan KS, Meads C. Does pelvic venous congestion syndrome exist and can it be treated? *Acta Obstet Gynecol Scand* 2012;91(5):525-8
- Monedero JL, Ezpeleta SZ, Perrin M. Pelvic congestion syndrome can be treated operatively with good long-term results. *Phlebology* 2012;27 Suppl 1:65-73
- Stones RW. Pelvic vascular congestion-half a century later. *Clin Obstet Gynecol* 2003;46(4):831-6
- Rundqvist E, Sandholm LE, Larsson G. Treatment of pelvic varicosities causing lower abdominal pain with extraperitoneal resection of the left ovarian vein. *Ann Chir Gynaecol* 1984;73(6):339-41
- Meneses L, Fava M, Diaz P, et al. Embolization of incompetent pelvic veins for the treatment of recurrent varicose veins in lower limbs and pelvic congestion syndrome. *Cardiovasc Intervent Radiol* 2013;36(1):128-32
- Beard RW, Kennedy RG, Gangar KF, et al. Bilateral oophorectomy and hysterectomy in the treatment of intractable pelvic pain associated with pelvic congestion. *Br J Obstet Gynaecol* 1991;98(10):988-92
- Edwards RD, Robertson IR, MacLean AB, Hemingway AP. Case report: pelvic pain syndrome – successful treatment of a case by ovarian vein embolization. *Clin Radiol* 1993;47(6):429-31
- Kim HS, Malhotra AD, Rowe PC, Lee JM, Venbrux AC. Embolotherapy for pelvic congestion syndrome: long-term results. *J Vasc Interv Radiol* 2006;17(2 Pt 1):289-97
- Kwon SH, Oh JH, Ko KR, Park HC, Huh JY. Transcatheter ovarian vein embolization using coils for the treatment of pelvic congestion syndrome. *Cardiovasc Intervent Radiol* 2007;30(4):655-61
- Chung MH, Huh CY. Comparison of treatments for pelvic congestion syndrome. *Tohoku J Exp Med* 2003;201(3):131-8