

# NECK MASSES AND FINE NEEDLE ASPIRATION

Matthew Hodder, MBChB; Navin Mani, MRCS

Neck masses are usually seen and primarily assessed by an ENT specialist; they may also be seen occasionally in general medicine. A good history and clinical examination is the first important step in their management.

## HISTORY

A thorough history is one of the most useful tools in developing a differential for neck masses. When considering malignancy the most important factors are the patient's age and the size and duration of the mass, as well as a history of smoking and alcohol consumption. In patients older than 40 years more than 60% of lesions are associated with malignancy. Acute symptoms such as sore throat, fever and cough suggest upper respiratory tract infections. Chronic symptoms such as alteration in voice quality, dysphagia or chronic sore throat are often associated with anatomic or functional alterations in the pharynx or larynx.

## EXAMINATION

The examination of the patient should involve general inspection of the neck for superficial lesions and asymmetry followed by palpation of all anatomical regions of the neck. Inspection of the oral cavity and examination of the larynx and pharynx by indirect or flexible laryngoscopy are also mandatory, which is why such patients should be assessed primarily by an ENT specialist.

## THE DIFFERENTIAL DIAGNOSIS

### Neoplastic

These can be benign or malignant. Benign masses are all characterised by slow growth and lack of invasion. They may be lipomas, haemangiomas, neuromas or fibromas. Malignant neoplasm can arise as a primary mass or a metastatic lesion. The common primary malignancies are thyroid cancer, salivary gland cancer, lymphomas and sarcomas. Less common are angiomas, paragangliomas and rhabdomyosarcomas. Metastatic spread often occurs from squamous cell carcinomas, melanomas and adenocarcinomas. The spread of such metastatic disease to lymph nodes where the primary is in the head and neck often follow well-defined patterns; most spread is to the lateral neck but malignancy in the oral cavity typically metastasise to the submandibular triangle.

### Congenital

In the anterior neck the thyroglossal duct cyst is the most common congenital cause of a neck mass. In the lateral neck brachial anomalies are the most common cause of neck masses which present anywhere along the path of the

sternocleidomastoid and may be cysts, sinuses or fistulae. These masses are typically painless, soft and slow growing, and there is often a history of infection with occasional spontaneous discharge. Other congenital masses include lymphangiomas, haemangiomas, ectopic thyroids and laryngoceles.

### Inflammatory

The most common inflammatory neck mass is due to cervical adenitis and is characterised by a painful swelling of normal lymph nodes due to infection or inflammation. Inflammatory masses are typically self-limited and resolve spontaneously over a few weeks; however, chronic inflammation can lead to permanent mass formation, often within the submandibular or parotid glands. Chronic sialadenitis as a result of salivary stones or duct stenosis can also result in gland hypertrophy and fibrosis. Infectious neck masses can arise from bacterial and viral infections; staphylococcus and streptococcus are the most common organisms cultured from neck abscesses. Other inflammatory causes for neck masses include granulomatosis, tuberculosis and sarcoidosis.

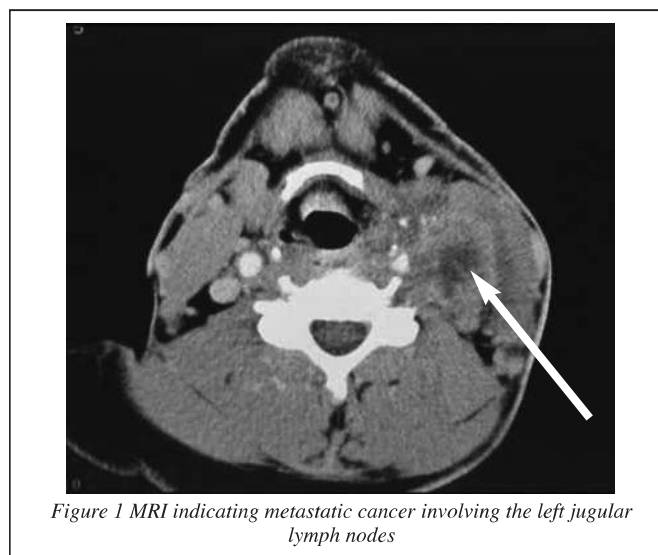


Figure 1 MRI indicating metastatic cancer involving the left jugular lymph nodes

## FINE NEEDLE ASPIRATION

Fine needle aspiration and cytology of a neck mass was first reported by Kun in 1847. Due to the high level of morbidity associated with the procedure it did not widely accepted at the time; however, fine needle aspiration of a solitary neck masses has been refined and is now a simple procedure that requires a few minutes to complete and is considered a safe and cost-effective procedure for diagnosing neck lumps.

### Method

Preparation of the patient involves routine blood tests and observations; antibiotic prophylaxis may be considered in

some patients. The patient should then be positioned comfortably so that the neck mass can be palpated easily. The skin is prepared using an alcohol preparation to create a sterile field. The mass is held in the left hand between thumb and index finger in a stable fixed position. A 10ml syringe with an 18- or 21-gauge needle is used and is placed percutaneously into the mass. Suction on the syringe begins once the tip of the needle has entered the mass. Without exiting the skin several passes are made through the mass. If the mass is cystic it should be completely drained before sending the evacuated fluid for cytology.

Following the aspiration a small drop of aspirated fluid is placed on a glass slide, from which a smear is made. Wet smears are placed in 95% ethyl alcohol and treated with the Papanicolaou technique, which stains giving good cellular detail. Cytology of this may indicate the cellular origin of a metastatic tumour. When the differential includes salivary, lymphoproliferative or fatty tumours, specimens should be air dried and prepared with a Wright-Giemsa stain.

Whilst it is considered safe there are some technical problems with fine needle aspiration which account for the 15-45% of samples which are inadequate for cytological diagnosis.<sup>(1)</sup> Some of the problems encountered include aspirating a mass without moving the needle sufficiently through cells to dislodge them and aspiration of skin or blood contaminating the sample. Also collection of necrotic or fibrotic specimens hampers the pathological diagnosis.

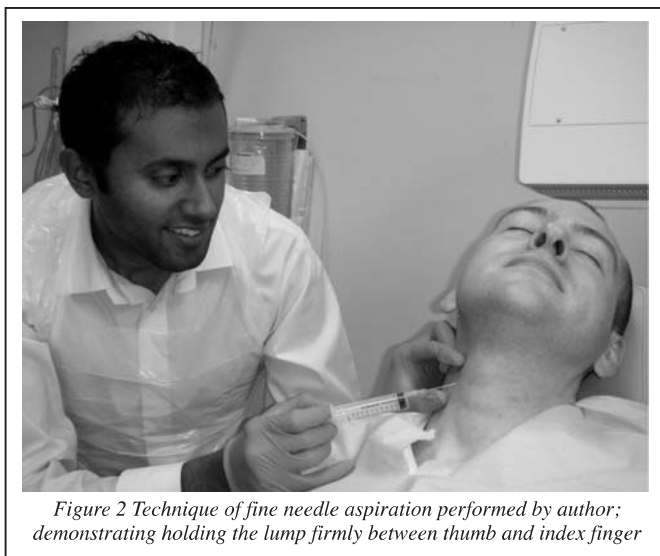


Figure 2 Technique of fine needle aspiration performed by author; demonstrating holding the lump firmly between thumb and index finger

### FINE NEEDLE VERSUS OPEN BIOPSY

There are many advantages of fine needle *versus* an open biopsy. Fine needle aspiration is a lot more convenient for patients who generally have less post-operative complications and require less time in hospital which equates to better patient satisfaction and reduced cost. Open biopsies have also been noted to interfere with future treatment;<sup>(2)</sup> they have been reported as making subsequent neck dissection/excision more difficult, causing tumour seeding or fungation, altering the normal lymphatic drainage of the neck and increasing the risk of post-operative local recurrence.

Fine needle aspiration has been demonstrated to show tumour deposition along the needle tract in animal models. Whilst this is not thought to be clinically relevant one study

showed that two of six patients with carcinoma who underwent fine needle aspiration with a 21-gauge needle had histological foci of tumour along the needle tracks.<sup>(3)</sup> However, another study used India ink to line the fine needle tracts in humans, and after excision and histological examination they found no signs of tumour cells lining the tract.<sup>(4)</sup>

Fine needle aspiration has been shown to have varying degrees of sensitivity and specificity for certain conditions. For example, it is almost 100% specific in diagnosing squamous cell carcinomas.<sup>(2)</sup> In thyroid nodules the correct pathology has been identified in approximately 95% of colloid goitres,<sup>(5)</sup> and 70% of Hashimoto's thyroiditis. A study in 2000 showed that for salivary glands fine needle aspirations were 84.8% sensitive and 93.7% specific, with an accuracy of 91.1%, which they suggested was adequate when combined with clinical history and examination.<sup>(6)</sup>

However, they are not as good at diagnosing follicular carcinomas as without the tumour capsule the angioinvasive character cannot be determined. Because of this, distinguishing a follicular adenoma from a well-differentiated follicular carcinoma has proved difficult, and as a result of the difficulty distinguishing benign from malignant the term follicular neoplasm is used, and this is an indication for thyroid surgery.

Open biopsy still has an important role to play in many cases, particularly if fine needle aspiration cytology has been non-diagnostic. Open biopsy is also required for definitive diagnosis of lymphomas.

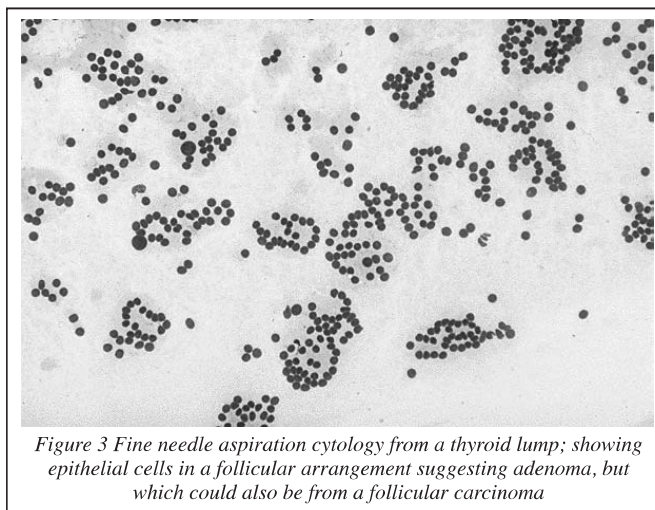


Figure 3 Fine needle aspiration cytology from a thyroid lump; showing epithelial cells in a follicular arrangement suggesting adenoma, but which could also be from a follicular carcinoma

### CONCLUSION

Fine needle aspiration has become an essential adjunct in the diagnosis of neck masses when combined with history and clinical examination, which must include fibre optic examination of the larynx and pharynx. It is established as a first-line investigation for neck lumps of unknown aetiology. Its ease of use and portability mean that it can be used in both the clinic setting and at the bedside. Fine needle aspiration of neck masses carries a learning curve for both the operator and the cytologist alike, but with experience high rates of accuracy in diagnosis are achievable.

**REFERENCES**

1. Baloch ZW, Sack MJ, Yu GH, Livolsi VA, Gupta PK. Fine-needle aspiration of thyroid: an institutional experience. *Thyroid* 1998;8(7):565-9
2. Birchall MA, Stafford ND, Walsh-Waring GP. Malignant neck lumps: a measured approach. *Ann R Coll Surg Engl* 1991;73(2):91-5
3. Mighell AJ, High AS. Histological identification of carcinoma in 21 gauge needle tracks after fine needle aspiration biopsy of head and neck carcinoma. *J Clin Pathol* 1998;51(3):241-3
4. Qizilbash AH, Sianos J, Young JE, Archibald SD. Fine needle aspiration biopsy cytology of major salivary glands. *Acta Cytol* 1985;29(4):503-12
5. Klemi PJ, Joensuu H, Nylamo E. Fine needle aspiration biopsy in the diagnosis of thyroid nodules. *Acta Cytol* 1991;35(4):434-8
6. Costas A, Castro P, Martin-Granizo R, Monje F, Marron C, Amigo A. Fine needle aspiration biopsy (FNAB) for lesions of the salivary glands. *Br J Oral Maxillofac Surg* 2000;38(5):539-42

**ENT STUDY DAY**

**Friday, 12 December 2008**  
**Education Centre, Royal Lancaster Infirmary**

**ENT Manifestations of Reflux Disease**

13:00–14:00 Lunch & pharmaceutical exhibition

**Session 1**

14:00–14:05 Introduction  
*Mr. M. Baraka*, Consultant ENT Surgeon, UHMB

14:05–14:10 Welcome  
*Mr. T. Bennett*, Deputy CEO, UHMB

14:10–15:00 ENT Manifestations of Reflux Disease  
*Mr. M. Watson*, Consultant Otolaryngologist, Head & Neck Surgeon,  
 Doncaster & Bassetlaw Hospitals NHS Foundation Trust

15:00–15:20 Patients seen in ENT department UHMB with lump in throat; audit.  
*Mr. A. Kochhar*, Associate Specialist, UHMB;  
*Mr. H. S. Aw Yeang*, CT2 ENT, UHMB

15:20–15:30 Discussion

15:30–16:00 Tea break & pharmaceutical exhibition

**Session 2**

16:00–16:30 Appropriate use of acid suppressant therapies.  
*Mr. R. Simmonds*, Pharmacist from Alchemy, working on NHS projects on behalf  
 of HDM Reckitt Benckiser

16:30–16:40 Discussion

16:45 Close

**Sponsored by:**  
**HDM Reckitt Benckiser**